

Aus der
Klinik und Poliklinik für Mund-, Kiefer- und Gesichtschirurgie
Klinik der Ludwig-Maximilians-Universität München

Direktor: Prof. Dr. Dr. Michael Ehrenfeld

**A Microbiological Study of Medication-Related Osteonecrosis of the Jaw
(MRONJ) and Actinomyces involvement in the disease**

Dissertation
zum Erwerb des Doktorgrades der Medizin
an der Medizinischen Fakultät
der Ludwig-Maximilians-Universität zu München

vorgelegt von
Sappasith Panya
aus
Bangkok, Thailand
2018

Mit Genehmigung der Medizinischen Fakultät
der Universität München

Berichterstatter: PD Dr. Dr. Sven Otto

Mitberichterstatter: Prof. Dr. Dr. Christoph Pautke
PD Dr. Jörg Hausdorf

Betreuung durch den
promovierten Mitarbeiter: Dr. Dr. Matthias Tröltzsch

Dekan: Prof. Dr. med. dent. Reinhard Hickel

Tag der mündlichen Prüfung: 01.03.2018

Eidesstattliche Versicherung

Panya, Sappasith

Name, Vorname

Lardprol64, 83

Straße, Hausnummer

10310, Bangkok, Thailand.

PLZ, Ort

Ich erkläre hiermit an Eides statt,

dass ich die vorliegende Dissertation mit dem Thema

A Microbiological study of Medication-related osteonecrosis of the jaw (MRONJ)
And Actinomyces involvement in the disease.

selbständig verfasst, mich außer der angegebenen keiner weiteren Hilfsmittel bedient und alle Erkenntnisse, die aus dem Schrifttum ganz oder annähernd übernommen sind, als solche kenntlich gemacht und nach ihrer Herkunft unter Bezeichnung der Fundstelle einzeln nachgewiesen habe.

Ich erkläre des Weiteren, dass die hier vorgelegte Dissertation nicht in gleicher oder in ähnlicher Form bei einer anderen Stelle zur Erlangung eines akademischen Grades eingereicht wurde.

Muenchen,02,03,2018

Ort, Datum

Sappasith Panya

Unterschrift Doktorandin/Doktorand

LIST OF CONTENTS

LIST OF CONTENTS	I
LIST OF FIGURES	IV
LIST OF TABLES	V
APPENDIX	VI
LIST OF ABBREVIATIONS.....	VII
1 INTRODUCTION.....	1
1.1 Medication-related osteonecrosis of the jaw (MRONJ): Review.....	1
1.1.1 Criteria (definition) of MRONJ.....	1
1.1.1 Classification of MRONJ	2
1.1.2 Antiresorptive medications	4
1.2 Pathophysiology of MRONJ	6
1.2.1 Hypotheses being proposed for MRONJ [4].....	6
1.2.2 Infection & inflammation hypothesis.....	8
1.3 Comorbidities, Risk and Local Factors of MRONJ.....	9
1.4 Evidence supporting infection theory: Is it trauma that triggers ONJ or pre-existing infection conditions?	10
1.5 Histopathological findings in MRONJ: infection & inflammation pictures are familiar	11
1.6 Previous microbiological study of MRONJ	12
1.6.1 Microorganism identification of MRONJ	12
1.7 Actinomyces finding in MRONJ.....	13
1.7.1 Characteristics of Actinomyces.....	13
1.7.2 Actinomyces with MRONJ	14
1.7.3 Actinomyces identification: Conventional culture vs Gene sequence analysis.....	14
1.8 Study Proposes	16
2 MATERIALS AND METHODS.....	17
2.1 Study population and Setting.....	17
2.1.1 Inclusion & Exclusion criteria.....	17
2.1.1.1 Inclusion Criteria	17
2.1.1.2 Exclusion Criteria	17

2.2	Data collection	18
2.3	Microbiological Study.....	19
2.4	Identification process.....	19
2.5	Statistical analysis	21
3	RESULTS.....	22
3.1	Descriptive study: Risk assessment in MRONJ patients.....	22
3.1.1	Patients Characteristics	23
3.1.1.1	Age & Gender.....	23
3.2	Cause of antiresorptive treatment.....	24
3.2.1	Antiresorptive agents.....	24
3.2.1.1	Application form of Antiresorptive drugs (ARD).....	25
3.3	Localization	26
3.4	Comorbidities	27
3.5	Prevention & Prophylaxis	28
3.6	Staging of MRONJ.....	28
3.6.1	Clinical presentation.....	29
3.6.2	Preceding events.....	30
3.7	Pathological Findings.....	31
3.8	Microbiological findings.....	32
3.9	Small group comparison.....	33
3.9.1	Swap Group.....	33
3.9.2	Chemotherapy Group	34
3.9.3	Smoking group	35
3.9.4	Steroid Group and Diabetes Group	37
3.10	Actinomyces identification	39
3.10.1	Culturing vs PCR.....	40
4	DISCUSSION	42
4.1	Pathological-Microbiological study of MRONJ	42
4.1.1	Pathophysiology	42
4.1.1.1	Pathological findings	42
4.1.2	Microbial identification.....	43
4.1.2.1	Microbiological comparison of findings in subgroups	44
4.1.3	Actinomyces findings.....	44

4.2	Patient characteristic, disease presentation, risk and initiation factors.....	46
4.2.1	Age, gender and underlying disease.....	46
4.2.2	Comorbidities.....	46
4.2.3	Preceding events.....	47
4.2.4	Antiresorptive drugs.....	48
4.2.5	Disease presentation and Localisation.....	48
4.2.6	Prevention and Prophylaxis.....	49
4.3	Limitation	50
5	CONCLUSION.....	51
6	SUMMARY.....	52
	ZUSAMMENFASUNG.....	53
7	REFERENCES	55
8	ACKNOWLEDGEMENTS.....	70
9	APPENDIX	71

LIST OF FIGURES

FIGURE 1: (UPPER LEFT AND RIGHT) CLINICAL PRESENTATION OF STAGE 0 MRONJ AND NECROTIC BONE SAMPLE FROM SURGERY. (LOWER LEFT AND RIGHT) CLINICAL PRESENTATION OF STAGE 2 MRONJ AND NECROTIC BONE SAMPLE.	4
FIGURE 2: BISPHOSPHONATE STRUCTURES AND APPROXIMATE RELATIVE POTENCIES FOR OSTEOCLAST INHIBITION [2].	5
FIGURE 3: PATIENT SELECTION FLOWCHART.....	22
FIGURE 4: AGE & SEX DISTRIBUTION	23
FIGURE 5: DISTRIBUTION OF THE VARIOUS ANTIRESORPTIVE DRUGS (IN PERCENT)	25
FIGURE 6: ROUTE OF DRUG ADMINISTRATION (IN PERCENT).....	25
FIGURE 7: DISTRIBUTION OF MRONJ LESION. LOCALISATION IN FDI TWO-DIGIT TOOTH NUMBERING SYSTEM	26
FIGURE 8: STAGING OF MRONJ LESION.....	29
FIGURE 9: ANAEROBIC BACTERIAL CULTURE OF A MRONJ SAMPLE. ACTINOMYCES SP. GROWN AS LARGE WHITISH COLONIES ARE INDICATED BY AN ARROW.....	32
FIGURE 10: MICROBIOLOGICAL PROFILING FROM BONE CULTURES. PERCENTAGE OF POSITIVE POPULATION (N = 136).....	33
FIGURE 11: MICROBIOLOGICAL BONE CULTURE PROFILING. COMPARISON BETWEEN SWAP CULTURE GR. AND BONE CULTURE GR.	34
FIGURE 12: MICROBIOLOGICAL BONE CULTURE PROFILING. COMPARISON BETWEEN NON-CHEMO GR. AND CHEMO GR.	35
FIGURE 13: MICROBIOLOGICAL BONE CULTURE PROFILING. COMPARISON BETWEEN NON-SMOKING GR. AND SMOKING GR.	36
FIGURE 14: MICROBIOLOGICAL BONE CULTURE PROFILING. COMPARISON BETWEEN NON-STEROID GR. VS STEROID GR.....	37
FIGURE 15: MICROBIOLOGICAL BONE CULTURE PROFILING. COMPARISON BETWEEN NON-DIABETES GR. AND DIABETES GR.	38
FIGURE 16: DETECTION OF ACTINOMYCES SP. USING A SPECIFIC REAL-TIME PCR. THE DIAGRAM SHOWS THE RESULTS OF POSITIVE SAMPLES WITH DISTINCT CYCLE THRESHOLD (CT)-VALUES INDICATING DIFFERENT NUMBERS OF ACTINOMYCES SP. IN THE RESPECTIVE PATIENT SAMPLES.....	39
FIGURE 17: ACTINOMYCES FINDINGS FROM REAL TIME PCR.....	40

LIST OF TABLES

TABLE 1: STAGING SYSTEM OF MRONJ [4]	3
TABLE 2: CAUSE OF ANTIRESORPTIVE DRUGS TREATMENT	24
TABLE 3: SUMMARY OF COMORBIDITIES	27
TABLE 4: SMOKING HABITS	27
TABLE 5: DENTAL PROFESSIONAL VISITED BEFORE ANTIRESORPTIVE THERAPY	28
TABLE 6: SUMMARY OF PATIENT CLINICAL PRESENTATIONS	30
TABLE 7: PRECEDING EVENTS BEFORE AN ONSET OF MRONJ	31
TABLE 8: SUMMARY OF PATHOLOGICAL FINDING	31
TABLE 9: CROSS TABLE DEFINING ACTINOMYCES FINDING BETWEEN BONE CULTURES AND REAL TIME PCR	41

APPENDIX

APPENDIX 1: COMMON ANTIRESORPTIVE AGENTS [124].....	71
APPENDIX 2: PATIENT HISTORY PARAMETER LIST	74
APPENDIX 3: LIST OF FINDING BACTERIA.....	76
APPENDIX 4: PUBLICATION LIST.....	77

LIST OF ABBREVIATIONS

AAOMS	American Association of Oral and Maxillofacial Surgeons
ARD	Antiresorptive drug
BD	Becton, Dickinson and Company
BLAST	Basic Local Alignment Search Tool
bp	base pairs
BPs	Bisphosphonates
BRONJ	Bisphosphonate-Related Osteonecrosis of the Jaw
Ct	Cycle threshold
contig	contiguous
CUO	Cancer of unknown primary origin
diff	different
Da	Dalton
EDT	Extended Direct Transfer method
FDI	Federation Dentaire Internationale
GmbH	Gesellschaft mit beschränkter Haftung
H&N	Head and Neck
MALDI-TOF	Matrix Assisted Laser Desorption Ionization – Time of Flight
microbiol	microbiological
MRONJ	Medication-Related Osteonecrosis of the Jaw
MS	Mass Spectrometry
MSP	Microspectrophotometry
m/z	mass-to-charge ratio
NBPs	Nitrogen containing Bisphosphonates
NCBI	National Center for Biotechnology Information
non-NBPs	non-Nitrogen containing Bisphosphonates
ONJ	Osteonecrosis of the Jaw
PCR	Polymerase chain reaction
PPi	Pyrophosphate
rep	report
RANKL	Receptor activator of nuclear factor kappa-B ligand
rRNA	ribosomal RNA
RT	Real Time

Sp.	Species
SPSS	Statistical Package for Social Sciences
SRE	Skeletal-Related Events

1 INTRODUCTION

Medication-related osteonecrosis of the jaw (MRONJ) has become a well-known side effect of antiresorptive and antiangiogenic drugs.

1.1 Medication-related osteonecrosis of the jaw (MRONJ): Review

This side effect emerged in 2003 as Bisphosphonate-related osteonecrosis of the jaw (BRONJ). In 2014, AAOMS (American Association of Oral and Maxillofacial Surgeons) changed the nomenclature from BRONJ to MRONJ due to the additional use of Denosumab as an antiresorptive drug. Antiresorptive drugs are used to reduce skeletal-related events in metastatic bone disease, multiple forms of osteoporosis (juvenile, postmenopausal or senile, glucocorticoid-induced, transplant-induced, immobility-induced, and androgen-deprivation-related) and heritable skeletal disorders in children [1, 2]. Osteonecrosis of the jaw (ONJ) was known at the beginning as “avascular necrosis of the jaw” [3].

MRONJ occurs worldwide especially in Europe and North America. Other particular side effects of antiresorptive drugs are an increased incidence of hypocalcemia, acute inflammatory response, musculoskeletal pain and atrial fibrillation.

1.1.1 Criteria (definition) of MRONJ

AAOMS has defined MRONJ based on patient history and on clinical findings as follows:

1. Current or previous treatment with antiresorptive or anti-angiogenic agents.
2. Exposed bone or bone that can be probed through an intraoral or extra oral fistula in the maxillofacial region that has persisted for more than eight weeks.

3. No history of radiation therapy to the jaws or obvious metastatic disease to the jaws [4].

1.1.1 Classification of MRONJ

MRONJ had been classified clinically and radiographically. Table 1 & Figure 1 represent clinical pictures and the details of AAOMS classification systems. The most commonly used classification is the one of AAOMS in 2014. Staging of MRONJ relies on clinical and radiographic examinations. It is necessary to ensure an accurate reflection of disease presentation and to assist in the appropriate stratification of patients.

Table 1: Staging system of MRONJ [4]

<i>Stage</i>	Clinical presentation	Management
<i>At risk</i>	No apparent necrotic bone in patients who have been treated with either oral or IV bisphosphonates	<ul style="list-style-type: none"> No treatment indicated Patient education
<i>Stage 0</i>	<p>No clinical evidence of necrotic bone, but non-specific clinical and radiographic findings and symptoms such as Non-exposed bone variant</p> <p>Symptoms:</p> <ul style="list-style-type: none"> odontalgia not explained by an odontogenic cause dull, aching bone pain in the body of the mandible, which may radiate to the temporomandibular joint region sinus pain, which may be associated with inflammation and thickening of the maxillary sinus wall altered neurosensory function <p>Clinical Findings:</p> <ul style="list-style-type: none"> loosening of teeth not explained by chronic periodontal disease periapical/periodontal fistula that is not associated with pulpal necrosis due to caries <p>Radiographic Findings:</p> <ul style="list-style-type: none"> alveolar bone loss or resorption not attributable to chronic periodontal disease changes to trabecular pattern—dense woven bone and persistence of unremodeled bone in extraction sockets regions of osteosclerosis involving the alveolar bone and/or the surrounding basilar bone thickening/obscuring of periodontal ligament (thickening of the lamina dura and decreased size of the periodontal ligament space) 	<ul style="list-style-type: none"> Systemic management, including the use of pain medication and antibiotics
<i>Stage 1</i>	<p>Exposed and necrotic bone or fistulae that probes to bone, in patients who are asymptomatic and have no evidence of infection.</p> <p>These patients may also present with radiographic findings mentioned for Stage 0, which are localized to the alveolar bone region.</p>	<ul style="list-style-type: none"> Antibacterial mouth rinse Clinical follow-up on a quarterly basis Patient education and review of indications for continued bisphosphonate therapy
<i>Stage 2</i>	<p>Exposed and necrotic bone, or fistulae that probe to bone, with evidence of infection as evidenced by pain and erythema in the region of the exposed bone with or without purulent drainage.</p> <p>These patients are typically symptomatic.</p> <p>These patients may also present with radiographic findings mentioned for Stage 0, which are localized to the alveolar bone region.</p>	<ul style="list-style-type: none"> Symptomatic treatment with oral antibiotics, Oral antibacterial mouth rinse Pain control Debridement to relieve soft tissue irritation and infection control
<i>Stage 3</i>	<p>Exposed and necrotic bone, or fistulae that probe to bone, with evidence of infection, and one or more of the following:</p> <ul style="list-style-type: none"> exposed necrotic bone extending beyond the region of alveolar bone, i.e., inferior border and ramus in the mandible, maxillary sinus and zygoma in the maxilla pathologic fracture • extra-oral fistula oral antral/oral nasal communication osteolysis extending to the inferior border of the mandible or sinus floor 	<ul style="list-style-type: none"> Antibacterial mouth rinse Antibiotic therapy and pain control Surgical debridement/resection for longer term palliation of infection and pain

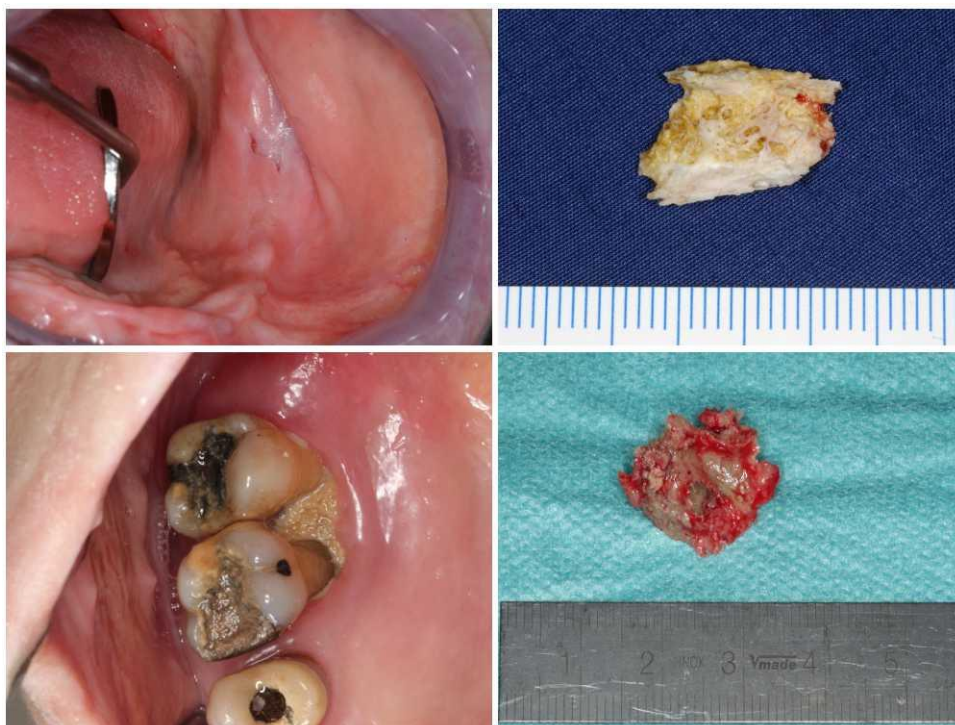


Figure 1: (Upper left and right) Clinical presentation of stage 0 MRONJ and necrotic bone sample from surgery. (Lower left and right) Clinical presentation of stage 2 MRONJ and necrotic bone sample.

1.1.2 Antiresorptive medications

Bisphosphonates are chemical derivatives of inorganic pyrophosphate (PPi) which are capable of binding to hydroxyapatite crystals like natural PPi. Bisphosphonates preferably incorporate into active bone remodelling sites, they inhibit hydroxyapatite breakdown, thereby effectively suppressing bone resorption [2, 6].

They can be divided structurally into nitrogen containing bisphosphonates (NBPs) and non-nitrogen containing bisphosphonates (non-NBPs) by the presence or the absence of an amino functional group in the molecule (Figure 2). NBPs are much more potent when compared to non-NBPs which were widely used in previous decades. The class of bisphosphonates, indication, dose / administration and their trade names are presented in Appendix 1.

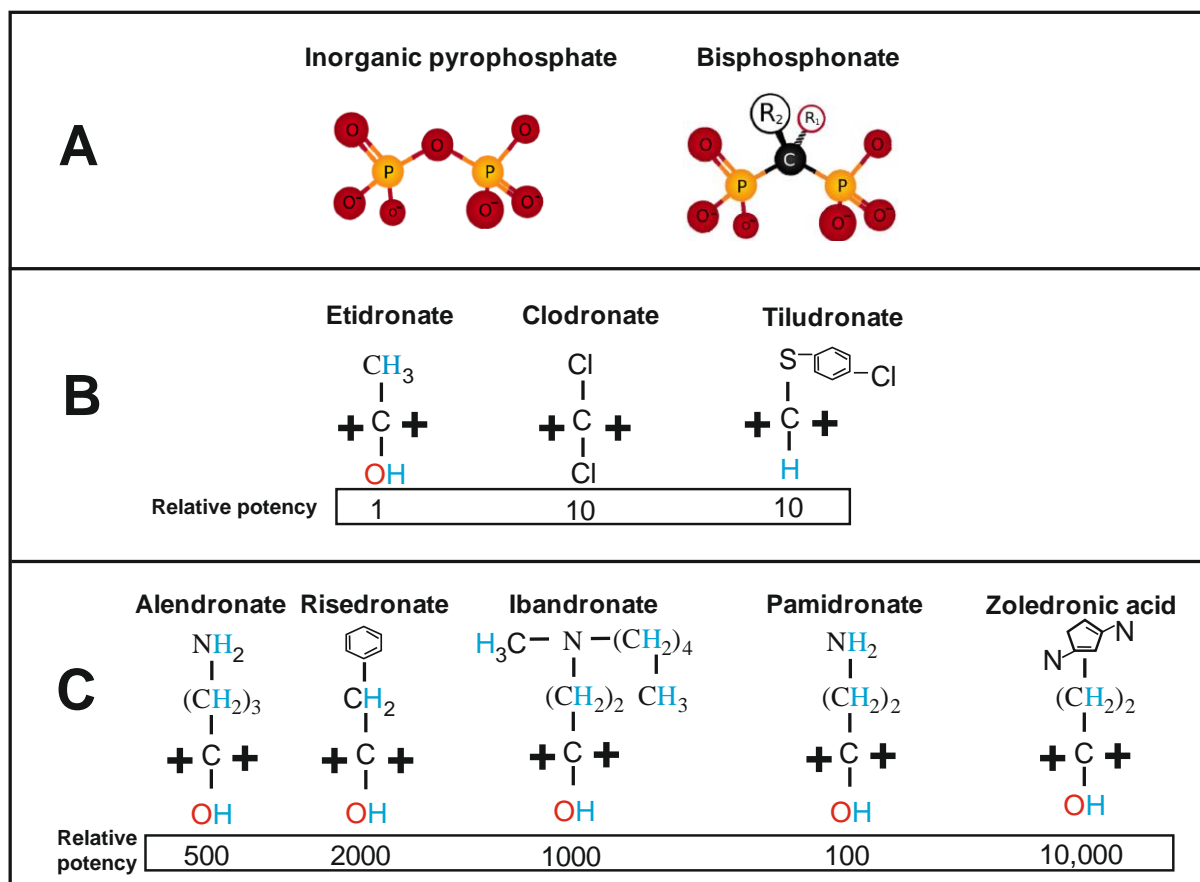


Figure 2: Bisphosphonate structures and approximate relative potencies for osteoclast inhibition [2]].

Bisphosphonates can be administered either intravenously or orally. Intravenous bisphosphonates (BPs) are widely used mainly to regulate skeletal-related events (SRE) correlated with bone metastasis in advanced solid tumours and bone lytic lesions of multiple myeloma and also in patients with osteoporosis. Oral bisphosphonates are mainly used to manage osteoporosis, osteopenia and other conditions such as Paget's disease and osteogenesis imperfecta [7, 8].

Denosumab is the most recent antiresorptive drug used which is a human monoclonal antibody that specifically binds to receptor activator of the nuclear factor kappa-B ligand (RANKL) inhibiting osteoclast function and bone resorption. Denosumab is different when

compared to the bisphosphonates having a shortened half-life. The effect on bone remodelling will decrease after 6 months of drug cessation and an inhibition will resolve within 1 year [9].

It is important to mention that MRONJ does not occur only due to the use of antiresorptive drugs (Bisphosphonates and Denosumab) but also due to the use of antiangiogenic drugs which can be divided into two subgroups: Monoclonal antibodies that block receptor or growth factor (bevacizumab) and small molecules that bind to tyrosine kinase receptor (sunitinib and sorafenib) [4].

Antiangiogenic medication acts by suppressing new blood vessels formation by blocking the angiogenesis-signalling cascade. They are beneficial in the treatment of gastrointestinal-, neuroendocrine tumours and renal cell carcinomas [4].

1.2 Pathophysiology of MRONJ

This disease has not been fully elucidated [9, 10].

1.2.1 Hypotheses being proposed for MRONJ [4]

Several hypotheses were proposed to explain why antiresorptive drugs cause MRONJ almost exclusively in the jaw bone: a) altered bone remodelling and induced osteoclasts apoptosis, b) angiogenesis inhibition, c) tissue toxicity, d) immune dysfunction, e) infection or inflammation. Each theory is explained in details as follows:

- a. Decrease of bone turnover by inhibition of osteoclast function: bisphosphonates and denosumab suppress osteoclast function leading to a reduction of bone remodelling that could cause osteonecrosis [11, 12, 13, 14]. Nitrogen-containing bisphosphonates act intracellularly by inhibiting farnesyl diphosphate synthase, which is needed in normal cellular function. Bisphosphonates are highly effective inhibitors of bone resorption that

selectively affect osteoclasts and also have direct effects on other cell types [11].

Denosumab binds to RANKL, preventing the maturation and differentiation of preosteoclasts and promotes apoptosis of osteoclasts. Bone resorption is therefore slowed [15].

b. Inhibition of angiogenesis: interruption of blood supply is one of a main causes of osteonecrosis [17, 18, 19]. Zoledronate can have antiangiogenic effects by inhibiting vascular endothelial cell growth factor proliferations. Bisphosphonates also reduce endothelial progenitor cell colony formation and migration (in vitro), thereby disturbing neovascularisation [20, 21]. By suppressing osseous angiogenesis and bone remodelling, bisphosphonates actualise bone necrosis in mice [22, 23].

c. Local toxicity: soft and hard tissue toxicity can lead to non-healing, exposed lesions in MORNJ [24, 25].

Apart from reducing osteoclasts activity bisphosphonates reduce the biological activity and viability of osteoblasts, epithelial cell, keratinocytes and fibroblast additionally. Moreover, the accumulation of bisphosphonates in tissue could cause direct toxicity to the oral epithelium and subcutaneous tissue. After an injury bisphosphonates are responsible for the delayed oral keratinocyte wound healing process. This could explain the high frequency of bone exposing lesions and delayed or unhealed wounds which turn into osteonecrosis lesions [26, 27].

d. Immunomodulation: antiresorptive drugs can modulate the activity of various cell types in human immune mechanism.

There is evidence that the cellular immune system (monocytes/macrophages, neutrophils and T-cell function) is suppressed by bisphosphonates (BPs). This could alleviate the response towards infection process [28, 29].

- e. Infection and inflammation: Inflammation has sustained as an important component of MRONJ.

1.2.2 Infection & inflammation hypothesis

MRONJ is presented clinically as necrotic bone that can be accompanied by pain, swelling, soft tissue inflammation, pus exudation, and or intra-/extraoral fistula. Antibiotics and antimicrobial control are normally recommended for MRONJ treatment. It commonly implies that an infectious component is generally involved in MRONJ development [4, 29, 30].

In vitro, bisphosphonates are reported to intensify adhesion of bacteria to hydroxyapatite and boost the rate of biofilm formation [31, 32]. It was found that microbial colonization in MRONJ cases was significantly greater than in bone necrosis in the absence of BPs, raising the possibility that BPs could increase bacterial and biofilm accumulation [33].

Moreover, immune response in MRONJ patients had been altered creating a negative environment that benefits opportunistic pathogens (Parvimonas, Peptostreptococcus, Fusobacterium, Eubacterium, Dialister and Gemella) [34]. It was found in animal models that bacterial stimulation could create MRONJ-like lesion in mice bone [35, 36].

One of the convincing arguments was that BPs would be released from the bone in an acidic environment (low pH value). In an inflammatory situation, BPs will slow an immune response which allows an infection to persist in the lesion, at the same time pathogens assist in creating an accumulation of BPs and toxin [37, 38]. This vicious cycle together with other

negative effect (bone turnover suppression, immunomodulation, tissue toxicity and avascularisation) may amplify a necrotic process of the jaw.

Therefore, infection is one of the most possible causes and an important factor developing osteonecrosis. However, the most reasonable answer could be that MRONJ occurs under a combination of all the above theories [39]. We considered the infection to be an important initiating factor.

1.3 Comorbidities, Risk and Local Factors of MRONJ

MRONJ is thought to be influenced by multiple factors [40]. Antiresorptive medication itself is considered as a primary risk factor including type (drug classification, potency & half-life), dose, frequency and the route of administration. Zoledronate has the highest potency in BPs and is related to more than 40% of MRONJ cases [41, 52]. High doses of intravenous bisphosphonates given in oncological condition were related to 94% of MRONJ cases which are much different in the oral bisphosphonates group [42]. The duration of the substance exposure was also claimed to be an important factor in MRONJ [41].

However, besides the antiresorptive drug itself several risk factors were published in previous studies [41]. Chemotherapy, Corticosteroids and co-morbid conditions such as anaemia and diabetes were reported to be correlated with an increased risk of MRONJ [43, 44, 45]. Chemotherapy drugs worsen MRONJ-like lesions in an animal model [22]. Smoking was also significantly associated with MRONJ development [46, 47]. Vitamin D deficiency shows a significant increasing incident rate of osteonecrosis in rats by dysregulated bone homeostasis and innate immunity [48]. Thalidomide, an immunomodulatory agent used in multiple myeloma patients could also aggravate early-stage MRONJ and may attribute disease progression to the jaw by inhibiting angiogenesis [49].

Trauma in form of tooth extraction is often mentioned as a preceding event of MRONJ. Preceding events such's long-term NBPs therapy and recent dental procedures are consistent findings in patients with MRONJ [50]; tooth extraction having the most negative influence in MRONJ staging [51]. Tooth extraction was reported in up to 60% of MRONJ cases [52, 54].

1.4 Evidence supporting infection theory: Is it trauma that triggers ONJ or pre-existing infection conditions?

Around 25% of MRONJ cases occur spontaneously [52, 53]. There is more stage 0 ONJ recently. Stage 0 category was added in 2009 AAOMS MRONJ-classification to include patients with non-specific symptoms, or clinical and radiographic abnormalities that may be due to the exposure to an antiresorptive agents [5]. In 2008, Junquera and Gallego presented two cases of this pathology without this clinical condition [56]. In 2010 Hutchinson, et al. had stage 0 disease with similar radiographic features of osteosclerosis in clinically symptomatic areas, most with an extension beyond the involved site [57]. In 2014, Aghaloo et al. also reported cases of stage 0 MRONJ in patients on denosumab and indicated the full-spectrum of similarities between BP- and denosumab-associated MRONJ clinically, radiographically, and histologically [58]. In our hospital (Department of oral and maxillofacial surgery, LMU), we found a stage 0 MRONJ patient which was treated conservatively and had a positive clinical response. Disease regression in radiological finding was also observed. This finding implies non-traumatizing MRONJ and should be further investigated.

MRONJ incidence is usually related to dental procedures and these are often performed in septic environment due to dental infection. Tooth extractions were performed in most of the previous reported cases of MRONJ. However, these teeth commonly had existing

periapical or periodontal diseases [5, 52, 60, 61]. In 2015, Ikeda T., et al. report successful Stage 0 MRONJ case treated with antibiotics alone [59].

Local infection together with tooth extraction can create a negative environment affecting MRONJ. At the same time, infection alone without micro trauma could cause spontaneous and stage 0 ONJ cases. We questioned if it is not tooth extraction itself, but rather prevailing infectious conditions that may be a key risk factor for the development of MRONJ [62].

1.5 Histopathological findings in MRONJ: infection & inflammation pictures are familiar

A diagnostic biopsy is often not performed in patient with MRONJ lesion because of possible wound healing disturbances. Pathological investigation normally has a role in confirming clinical diagnosis after surgery [28, 116].

Microscopic images of MRONJ were normally presented with necrotic bone with irregular peripheral resorption and often surrounded by bacterial colonies [63]. The empty Howship lacunae at a peripheral area display an osteoclast's apoptotic figure [64]. Intertrabecular spaces were infiltrated with inflammatory cells such as neutrophils, lymphocytes and plasma cells [65, 66, 67].

Filamentous form bacteria and focal acute inflammation were found [68, 68]. Actinomyces are one of a common microorganisms in histological findings [70, 71, 72, 73]. Infection impression and bacterial accumulation are typically shown in Histological-pathological reports.

1.6 Previous microbiological study of MRONJ

Seven hundred and fifty different bacterial species were found in the oral cavity [74]. A microbial biofilm is a community of microorganisms attached to a surface and surrounded by a matrix of extracellular polymeric substance [75]. Biofilm organisms are embedded in a matrix of extracellular polymeric substances that they have produced in order to connect to and communicate with each other, and exhibit an altered phenotype in terms of growth rate, gene transcription and antimicrobial resistance [76, 77].

Polymicrobial infection and periodontal disease may contribute to development of MRONJ as a biofilm associated infection [78]. Infection of the denuded bone and the creation of a biofilm composed of gram-positive and gram-negative strains and anaerobes have been documented [79].

1.6.1 Microorganism identification of MRONJ

In previous studies, gram-positive and negative organisms have been reported in biofilms of MRONJ patients. Aerobes, anaerobes and facultative anaerobes were found [79]. Common species were Genus Fusobacterial, Bacillus, Actinomyces, Staphylococcus, Streptococcus, Selenomonas and Treponemes. Candida species were also observed in almost all of the samples. Anaerobes showed a dominant role, suggesting an inhibited angiogenesis in MRONJ [79].

There were not many previous microbiological reports from bone sample biopsies. One control-cohort study with molecular bacterial identification (from 15 samples) showed a significant difference in bacterial genera between MRONJ bone samples and control groups. Parvimonas, Peptostreptococcus, Fusobacterium, Eubacterium, Dialister and Gemella were reported [34]. In another study, 12 infected bone samples (6-MRONJ and 6 normal infected

bone) culture and molecular profiling reported that *Streptococcus*, *Eubacterium*, and *Pseudoramibacter* were peculiar to MRONJ lesions compared to normal infected bone [30].

All previous studies had the same limitation of a small subject number of culture samples which lead to our study objective.

1.7 Actinomyces finding in MRONJ

Actinomyces are gram-positive pleomorphic, anaerobic to microaerophilic, filamentous, non-motile, non-spore-forming bacteria that can be found in calculus, periodontal pockets, carious lesions and oral mucosal surfaces, in addition to the upper respiratory, gastrointestinal tracts and female genital mucosa [80, 81, 82].

1.7.1 Characteristics of Actinomyces

Actinomyces are one of the dominating genera in the oral cavity. At least 25 species have currently been published of human specimen and 8 (*A. gorgiae*, *A. gerencseriae*, *A. gravenitzi*, *A. israelii*, *A. meyeri*, *A. naeslundii*, *A. odontolyticus* and *A. oris*) of them from the oral cavity [83]. Orocervicofacial actinomycosis is the most common actinomycosis which was found in more than 50% of all cases [84, 85]. Actinomyces species are mainly associated not only with cervicofacial actinomycosis but also with oral or cerebral abscesses, dental caries and periodontitis [86, 87]. They also seem to play a greater role than expected in the pathogenesis of osteoradionecrosis and MRONJ.

Actinomyces do not cause disease as long as they stay on the surface of the mucosa. However, if the integrity of the mucosal barrier is compromised and the bacteria gain access to the oral tissues or jaw bone, they may initiate a prolonged chronic inflammatory process, creating a tumour-like mass, tissue destruction, osteolysis, and multiple sinus tracts named “Actinomycosis” [86].

1.7.2 Actinomyces with MRONJ

Actinomyces are one of the most common findings in many MRONJ microbial reports [70, 88, 89, 90, 91]. A report found a significant symptoms improvement in MRONJ (symptoms free) after Actinomyces treatment with antibiotic [80].

There are histopathological reports among osteoradionecrosis and MRONJ patients, showing direct association of actinomyces colonies with bone lesions. The filamentous, anaerobe actinomyces has long been associated with the necrotic bone found in MRONJ lesions, but the exact role of the bacteria is still unclear [92, 93]. One report found up to 90% (9/10) positive finding of actinomyces accumulation in bone sample biopsy of MRONJ [94].

1.7.3 Actinomyces identification: Conventional culture vs Gene sequence analysis

It is unreliable and challenging to identify Actinomyces with conservative methods [93]. Actinomyces identification is possible under microscopic investigation. At present with gram-positive branching filamentous organisms. However, results should be interpreted cautiously with a relevant clinical history, signs and symptoms [83].

Actinomyces culture needs 48 hours of incubation period or longer under anaerobic conditions and the definitive identification may take 2-3 weeks [81]. Most actinomyces species could be identified using conventional biochemical tests but this is still challenging [94]. Indifferent growth in media frequently lead to false-negative actinomyces culture results and poor reproducibility. To date, it is recognized that it may result in misidentification of clinical isolates of Actinomyces by using conventional and biochemical test.

16S rRNA gene sequence analysis, which was originally used to reconstruct an organism phylogenetic relationship, is in recent years an alternative method. It can provide far more precise identification [83, 95].

To differentiate from culture method, gene sequencing with PCR has more sensibility because of the amplification ability with high fidelity. The ability to detect non-vital genetic substance from specimen and amplifying was the advantage in this method [93]. In 2013, Kaya D, et al. compared PCR with culturing and microscopic identification for accurate diagnosis of genital actinomyces. This study shows that PCR is the most sensible and reliable detection method.

Some previous studies refused actinomyces signification by finding MRONJ lesions without actinomyces infection [55]. However, we believe that there is still a detection missing of actinomyces in conventional methods.

1.8 Study Proposes

The main objectives of this thesis are:

1. To identify the bacterial profile in MRONJ bone samples from culture reports.
2. To confirm the involvement of actinomyces in the infectious aspect of MRONJ by using PCR.
3. To add more information on MRONJ characteristics as well as risk factors for developing MRONJ.

2 MATERIALS AND METHODS

2.1 Study population and Setting

This study was a single centre retrospective study carried out at the oral and maxillofacial surgery department, Ludwig-Maximilians-University, Munich, Germany to identify all patients with MRONJ from January 2003 to December 2015. Ethic Votum nr: 145-16

2.1.1 Inclusion & Exclusion criteria

2.1.1.1 Inclusion Criteria

- i) MRONJ patients were diagnosed based on AAOMS position paper [4].
 - a. Current or previous treatment with antiresorptive or antiangiogenic agents.
 - b. Exposed bone or bone that can be probed through an intraoral or extraoral fistula(e) in the maxillofacial region that has persisted for more than eight weeks.
 - c. No history of radiation therapy to the jaws or obvious metastatic disease to the jaws.
- ii) MRONJ patients with microbiological examination.

2.1.1.2 Exclusion Criteria

To minimize confounding variables or effect modifiers, i) patients missing clinical, radiographic, or follow-up data; ii) if they had a history of head and neck radiation as this can cause osteonecrosis unrelated to antiresorptive drugs; iii) missing information or inappropriate microbiological technique

To validate culture results and minimize technique variation, according to our expert consultant opinion, we excluded all samples with: i) different culture technique (only bone sample biopsy accepted) and ii) all reports before 2008 (due to different culturing technique and microorganism identifying index).

2.2 Data collection

Patient's records were screened and a separate data sheet was designed to be filled out with the information for each included patient. With a detailed history concerning clinical presentation: age, sex, location of the lesion, primary cause of antiresorptive treatment, comorbidities, clinical presentation, MRONJ clinical staging, the type of antiresorptive drug, the route of administration, the treatment course, the pathological findings of bone specimens obtained from surgeries.

All cases underwent radiographic evaluation with at least panoramic radiograph to rule out other aetiologies of jaw necrosis before surgical intervention. Surgery was performed only in patients with good general health status. Antiresorptive therapy was not generally interrupted during and after the surgical procedure unless the oncologist believed the patient needed a break as part of the cancer drug therapy (individual decision after discussion with an oncologist). All surgical procedures took place in the same unit.

Bone samples were collected and sent for pathological, microbiological investigation and PCR (for actinomyces, if possible). One sample of bone from each patient affected by MRONJ in our study was cut into sub fragments and i) send for pathological examination to confirm MRONJ diagnosis and to look for signs of ongoing infection & inflammation. ii) prepared for microbiological analysis as described below.

2.3 Microbiological Study

A collaboration was done between the oral and maxillofacial department (Head: Prof. Dr. Michael Ehrenfeld) and Max-von Pattenkofer Institute of Microbiology directed by Prof. Dr. Sören Schubert, Grosshaden, Munich. All the microbiological tests were performed in the same lab.

2.4 Identification process

Classical bacterial diagnostics were used for the bone samples. For this, aerobic cultures were prepared on Columbia blood-agar, MacConkey-agar and Columbia-CAN-agar, anaerobic cultures on Schaedler-agar and Schaedler-KV-agar (all agar plates from BD, Heidelberg, Germany). Besides, the swabs were cultivated in thioglycolate broth. All aerobic cultures have been read after 24h, 48h and 72h, the anaerobic cultures after 2d, 5d and 7d. The bacterial counts have been enumerated semi-quantitative and bacterial colonies were objected to MALDI-TOF MS for further species identification.

Samples were evaluated by the use of Microflex LT mass spectrometer (Bruker Daltonik GmbH, Bremen, Germany) in linear positive-ion mode across the m/z range of 2,000 to 20,000 Da. Each spot was measured by using 240 laser shots at 60 Hz in groups of 40 shots per sampling area of the spot. Spectra were analyzed by using MALDI Biotyper software (v 3.1 – Build 65). Sample preparation included either the “direct transfer method”, the “Extended Direct Transfer method (EDT)” or the “ethanol/formic acid extract method” as previously described [17]. Resulting spectra were compared against reference spectra using Bruker MALDI-TOF Biotyper software to obtain identification with a confidence score. For most isolates, the MSP (Main Spectral Projection) reference spectra were those contained in the Bruker database of 2013 (database version V 3.3.1.2) containing 364 genera, 2185 species and 4613 individual MSP. Results with score >2 were considered as correct species

identification, results displaying values of $1.5 \leq$ and ≤ 2 were accepted as correct genus identification.

Identification of bacteria by sequencing of 16S rDNA has been performed as described previously with some modifications [18]. In brief, crude bacterial lysates were prepared directly from culture plates by suspending bacteria from a clonal culture in 100 μ l of RT-PCR grade water (approximately McFarland Standard 2.0) and placed in a hot block at 100 °C for 10 min. A ~800 bp-fragment of 16S rDNA was amplified using the universal primer pair FD1 5'-AGAGTTTGATCCTGGCTCAG-3' and 800r 5'-GAGTACCAGGGTATCTAATCC-3'. Resulting PCR amplicons were sequenced using the same primers and standard sequencing methods. Data from both strands were aligned in SeqMan (DNASTAR Lasergene 8 Suite) to generate a contig of around 800 bp. The consensus sequences were then used to compare with online databases (NCBI BLAST—<http://blast.ncbi.nlm.nih.gov/Blast.cgi>) and the Ribosomal Database Project (<http://rdp.cme.msu.edu/>). Identification criteria of 99% sequence identity for identification to species level were applied [19], where matches had to be to the species type strain. The identities of type strains, as well as accession numbers in NCBI for equivalent 16S rDNA sequences, are available at <http://www.bacterio.cict.fr/> for all validly published bacterial species.

According to the suggestion of our experienced microbiologist (Prof. Schubert), Species from culture results were grouped into 14 categories:

- | | |
|---------------------------------|-----------------------|
| 1 = Actinomyces sp. | 2 = Bacteroides sp. |
| 3 = Enterobacter gr. | 4 = Fusobacterium sp. |
| 5 = Prevotella sp. | 6 = Streptococcus gr. |
| 7 = Enterococcus sp. | 8 = Candida sp. |
| 9 = Haemophilus sp. | 10 = Neisseria sp. |
| 11 = Porphyromonas sp. | 12 = Veillonella sp. |
| 13 = Mixed flora of oral cavity | 14 = Miscellaneous |

Due to high likelihood of false positive culture from environmental exposure, we considered only at least strongly positive +2 culture result as positive culture [positive (+1) and mild positive (+) will be excluded].

Bacteria profiling was done also in a small group to see if it has a different outcome in culture results (Sub group analysis) such as:

- swap culture vs bone culture
- patients with chemotherapy vs without chemotherapy
- patients with tobacco use vs non-tobacco group

From pathological finding, we were looking not only for dead bone to confirm MRONJ diagnosis but also for signs of infection & inflammation such as inflammatory cell infiltration, bacterial colonization and specifically presentation of filamentous forming bacteria (Actinomyces). This investigation was done to enhance the value of bacterial profiling by confirming active infection in bone samples.

2.5 Statistical analysis

Statistical analysis was performed using SPSS version 22.0 (SPSS Inc., Chicago, IL, USA). Results are expressed as mean values including standard error of the mean and range. Means were compared by statistical testing (Student's t-test), where $p < 0.05$ was considered to be significant.

3 RESULTS

3.1 Descriptive study: Risk assessment in MRONJ patients

The medical and dental records of 209 patients diagnosed with MRONJ and evaluated with microbiological investigation, from first of January 2003 till the end of December 2015, were reviewed. Of those patients, 136 patients fulfilled the inclusion criteria and were included in this thesis (see Figure 3).

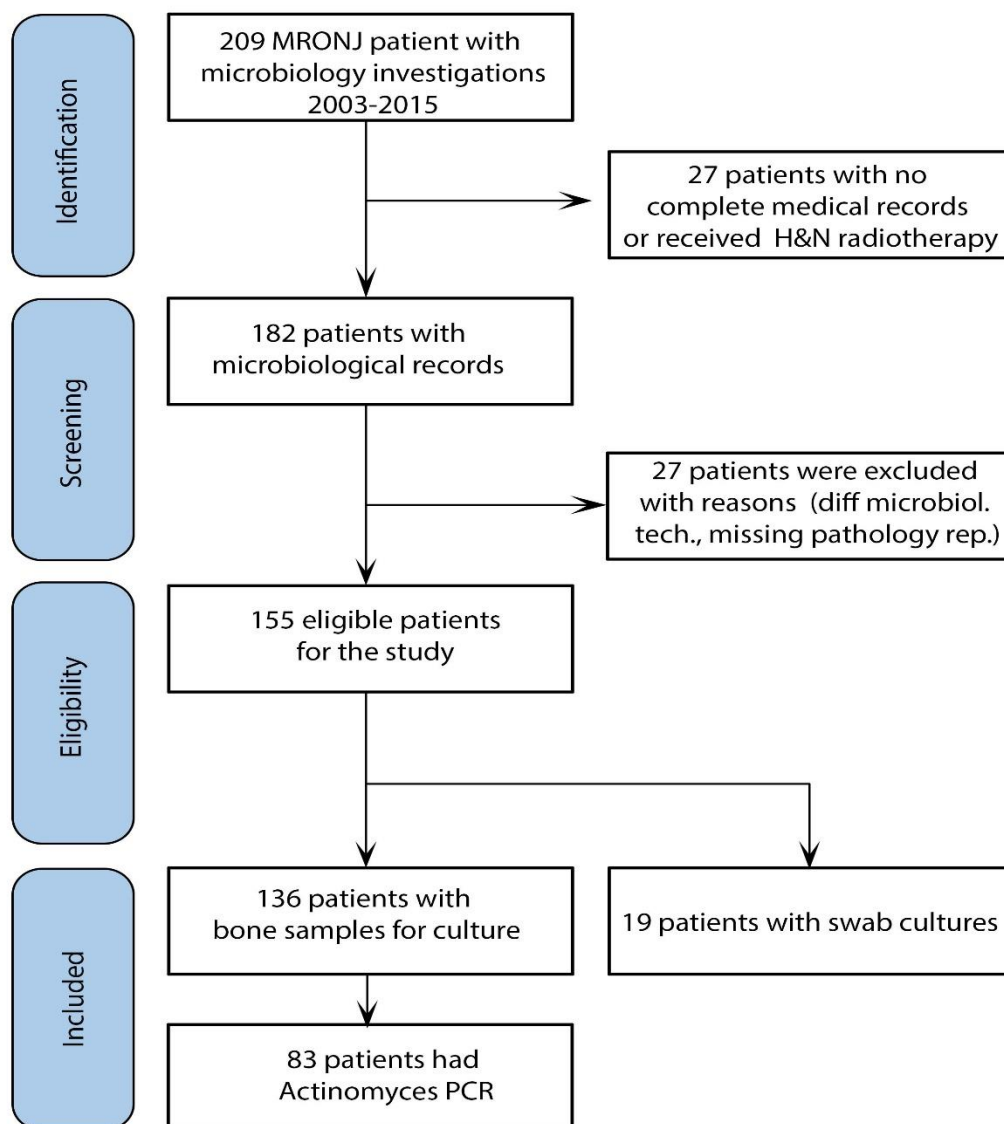


Figure 3: Patient selection flowchart

3.1.1 Patients Characteristics

The demographic characteristics of these patients were summarized as below (Total n=136).

3.1.1.1 Age & Gender

The mean age of the patients was 70.1 years \pm 8.83 SD; 53 (39 %) of the patients were males and 83 (61%) were female. The mean age of both genders were similar (male 71.2 and female 69.4).

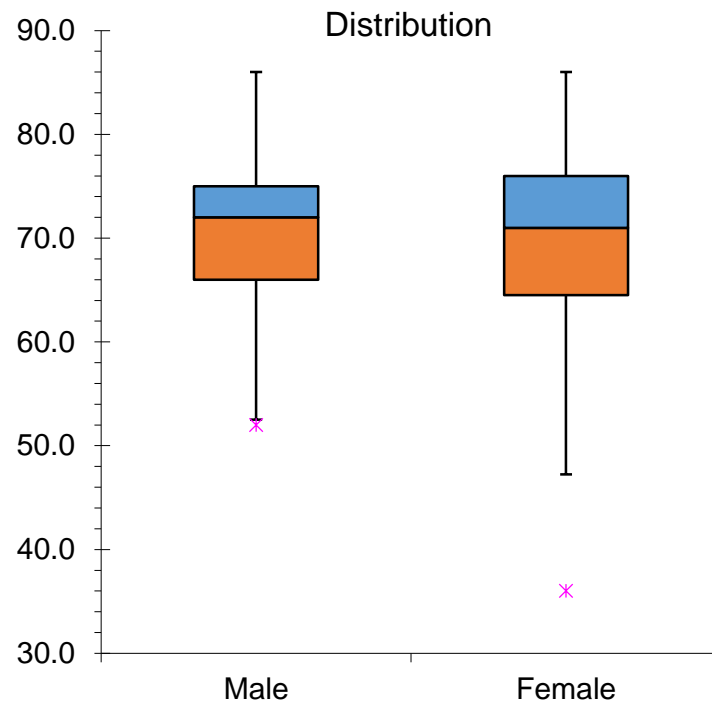


Figure 4: Age & Sex distribution

3.2 Cause of antiresorptive treatment

Breast cancer was the most called cause for the administration of antiresorptive drugs n=50 (36.8%), followed by prostate cancer n=31 (22.8%) and multiple myeloma n=17 (12.5%). The remainder were diagnosed with osteoporosis n=18 (13.2%) and lung cancer n=4 (2.9%).

Most of the female patients had breast cancer (59%) while prostate cancer was most common in male patients (58.4%).

Table 2: Cause of antiresorptive drugs treatment

Cause of ARD	male	female	total, n (%)
Breast cancer	1	49	50 (36.8)
Prostate cancer	31	0	31 (22.8)
Multiple myeloma	8	9	17 (12.5)
Osteoporosis	3	15	18 (13.2)
Lung cancer	3	1	4 (2.9)

Other causes included: colon cancer, systemic mastocytosis, renal cancer, CUO (cancer with unknown origin), bladder cancer, thyroid cancer, endometrium cancer make up 11.7% (16 from 136) of all samples.

3.2.1 Antiresorptive agents

Among the ARD groups, the largest population 71 (52.2%) received zoledronate alone, 5 (3.7%) received pamidronate alone, 5 (3.7%) received ibandronate, 38 (27.9%) received combination of BPs and 17 (12.5%) received denosumab.

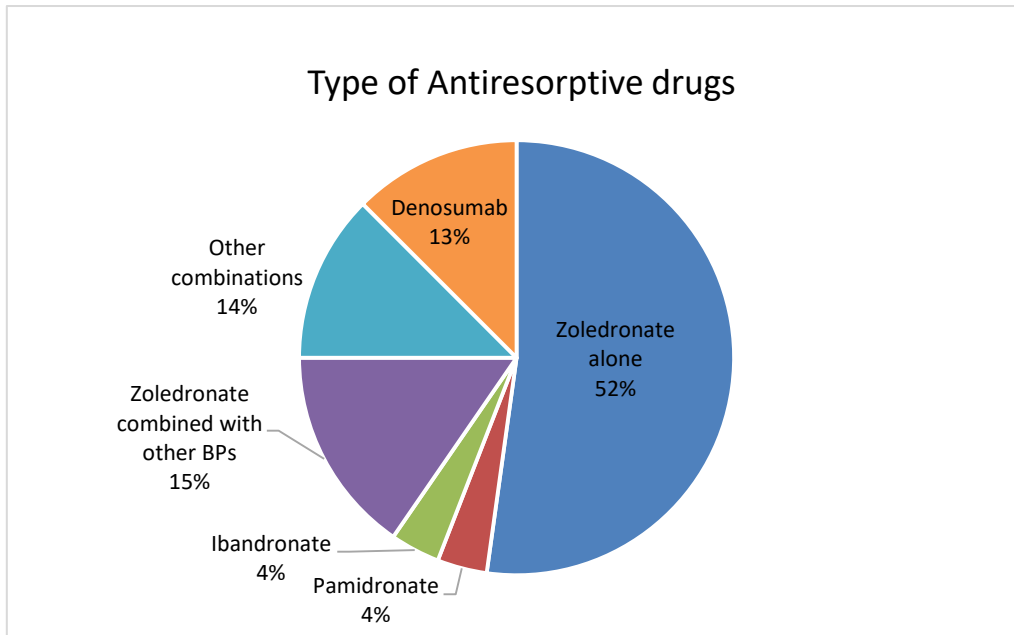


Figure 5: Distribution of the various antiresorptive drugs (in percent)

3.2.1.1 Application form of Antiresorptive drugs (ARD)

Most of the patients, 110 (80.9%) received intravenous ARD, 9 (6.6%) received oral form and 17(12.5%) received subcutaneous injections.

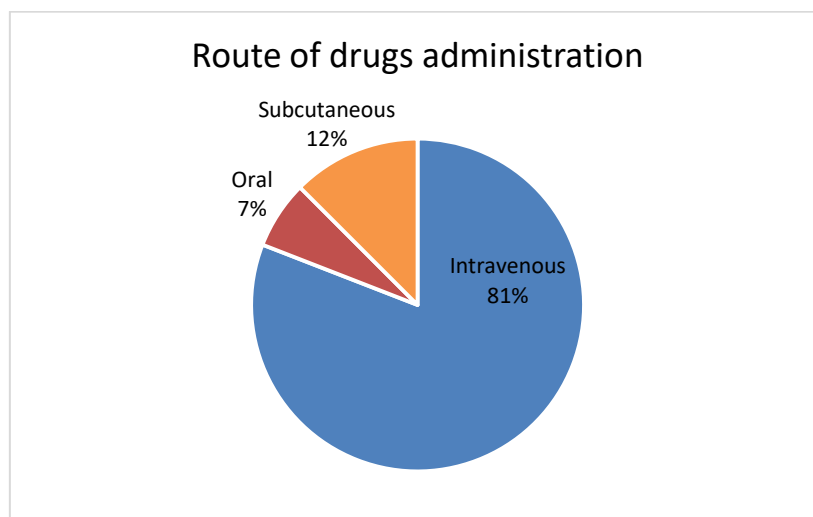


Figure 6: Route of drug administration (in percent)

3.3 Localization

Most of the patients had lesions in the mandible. 58% in the mandible alone, 15% had lesion in both jaws and 26.5% in the maxilla alone. 39% of patients had lesions located on right side only, while 36% of patients had lesions on the left side only and around 24% had lesions on both sides.

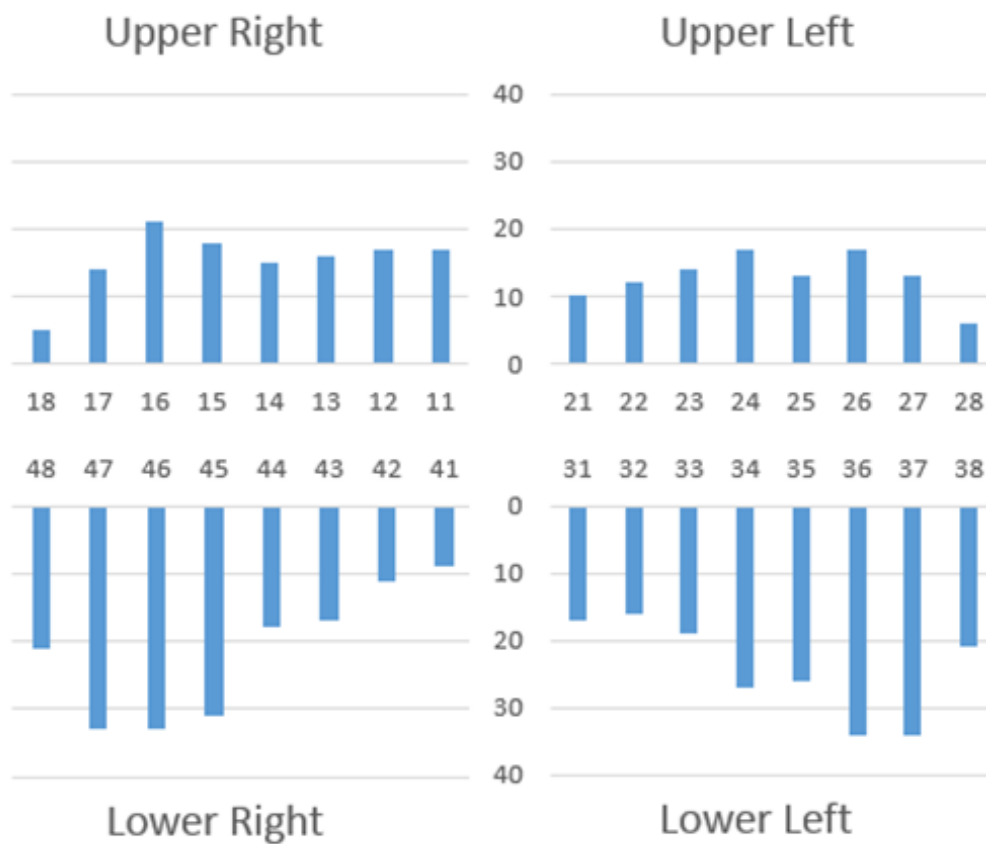


Figure 7: Distribution of MRONJ lesion. Localisation in FDI two-digit tooth numbering system

3.4 Comorbidities

The relevant comorbidities, identified in 136 patients, included diabetes mellitus (n=26, 19.1%), chemotherapy (n=80, 58.8%), history receiving body irradiation (apart from head and neck radiation) (n=61, 44.9%).

Thirty three patients received steroid treatment (24.3%) and 3(2.3%) received immunomodulation drugs (thalidomide).

Thirty eight patients report of past smoking habits (27.9%) and 21 from 38 were still smoking (15.4).

Table 3: Summary of comorbidities

Comorbidities	n(%)
Metastatic bone	92 (67.6)
Other skeletal disease	21 (15.4)
Diabetes	26 (19.1)
Cardio vascular disease	47 (34.6)
metastasis in organs	38 (27.9)
Hx of Chemotherapy	80 (58.8)
Hx of Body radiation	61 (44.9)
history of steroid intake	33 (24.3)
Thalidomide	3 (2.3)

Table 4: Smoking habits

Smoking habits	n(%)
no smokers	98(72.1)
used to smoke	17(12.5)
still smoking	21(15.4)

3.5 Prevention & Prophylaxis

We could prove that 3% of patients had visited a dentist or an oral surgeon before receiving antiresorptive drugs. After diagnosis as MRONJ most of the patients (82.3%) stopped antiresorptive drugs permanently (25.7%) or temporary (56.6%) and 17.6% of patients could not.

Table 5: Dental professional visited before antiresorptive therapy

Visited before antiresorptive therapy	n(%)
yes	4(2.9%)
no	132 (97.1%)
Break from antiresorptive drugs	n(%)
never	24(17.6)
permanent	35(25.7)
temporary	77(56.6)

3.6 Staging of MRONJ

The patients were stratified into categories according to the known antecedents or spontaneous development of MRONJ as in Table 1.

Only one case referred to stage 0 with no bone exposure but uncharacteristic signs and symptoms of MRONJ. 22 cases were categorized as stage 1 where bone was exposed in the absence of pain and signs of infection. The majority of cases (n = 82) were classified as stage 2 based on exposed necrotic bone in the maxillofacial region accompanied by pain or signs of infection. 31 cases were stage 3 lesions due to complications such as pathological fracture, extraoral fistula formation, extension of the lesion to the inferior border of the mandible or to the floor of the maxillary sinus.

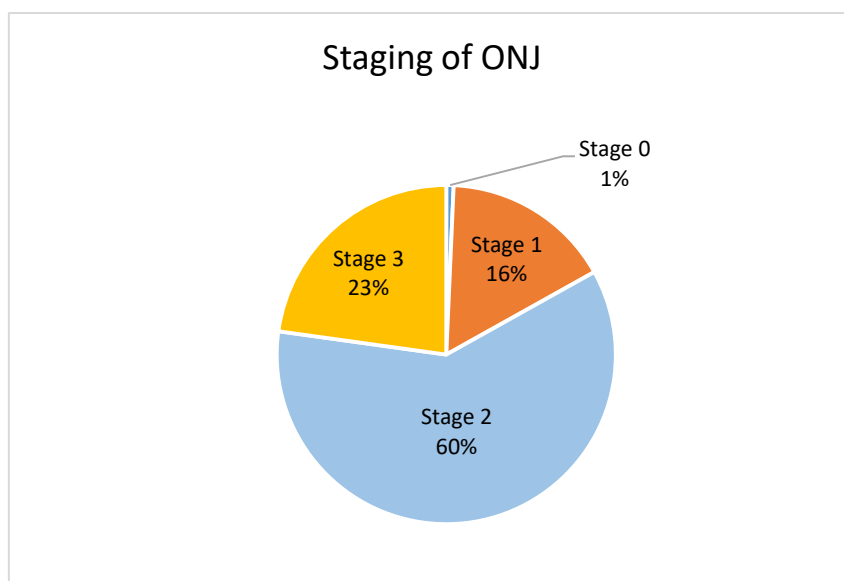


Figure 8: Staging of MRONJ lesion

3.6.1 Clinical presentation

The clinical signs of MRONJ could start from burning sensation (stage 0) to silently exposed bone lesion (stage 1) to mandibular pathologic fracture (stage 3). Most of the patients presented with MRONJ in the mandible and 21 patients had involvement of the maxilla and mandible.

Regarding the onset of MRONJ, the initial symptom was inflammation in 84 patients (61.8%), pain in 108 patients (79.4%) and visible exposed bone in 106 patients (77.9%). Signs and symptoms that also occurred were: disturbances in wound healing in 86 patients (63.2%), suppuration in 64 patients (47.1%), pathological fracture in 12 patients (8.8%), intra-and extraoral swelling in 77 patients (56.6%) and fistula formation in 46 patients (33.8%).

Eleven from 100 Mandible lesions showed inferior alveolar nerve involvement also 18 maxillary sinus involvement from 57 maxillary lesions.

Table 6: Summary of patient clinical presentations

Clinical presentation	n(%)
Visible exposed bone	106 (77.9)
Pain during the course	108 (79.4)
Disturbances in wound healing	86 (63.2)
Signs of local inflammation	84 (61.8)
Pus presentation	64 (47.1)
Pathological fracture	12 (8.8)
intra- or extraoral swelling	77 (56.6)
intra- or extraoral fistula	46 (33.8)
Clinical presentation	n(%)
Maxilla-sinus involvement (from 57 Maxilla lesion)	18 of 57 (13.2)
Mandibular N. sensibility disturbance (from 100 Mandible lesion)	11 of 100 (8.1)

3.6.2 Preceding events

Relevant preceding events were tooth extractions in (n=73, 53.7%) of the lesions involved and (n=16, 11.8%) of the patients that underwent other dentoalveolar surgery. (n=16, 11.8%) received periodontal treatment and (n=6, 4.4%) of the patients had denture pressure sores. Around 18.4% had no intervention in the lesion area.

Table 7: Preceding events before an onset of MRONJ

preceding events	n(%)
extractions	73 (53.7)
dentoalveolar surgery	16 (11.8)
periodontal lesion & treatment	16 (11.8)
denture sore	6 (4.4)
spontaneous	25 (18.4)

3.7 Pathological Findings

The pathological report for all patients (n=136) was in accordance with pre-operative diagnosis of MRONJ. Almost all (98%) showed necrotic bone pattern and 94% presented inflammatory processes: neutrophils, lymphocytes or plasma cells infiltration.

Around three-fourth (n=101,74.3%) of the samples showed bacterial colonization and 33% showed filamentous form rod shape bacteria which suggested actinomyces species.

Table 8: Summary of pathological finding

finding (total n = 136)	n(%)
necrotic bone	133 (97.8)
inflammatory process	127 (93.7)
bacterial clumping	101 (74.3)
Actinomyces like bacteria	46 (33.8)

3.8 Microbiological findings

One hundred and fifty-five patients had either bone or swap culture. One hundred and eleven patients had at least one microorganism strong positive finding. Sixty-nine different species were found. (Appendix 2)

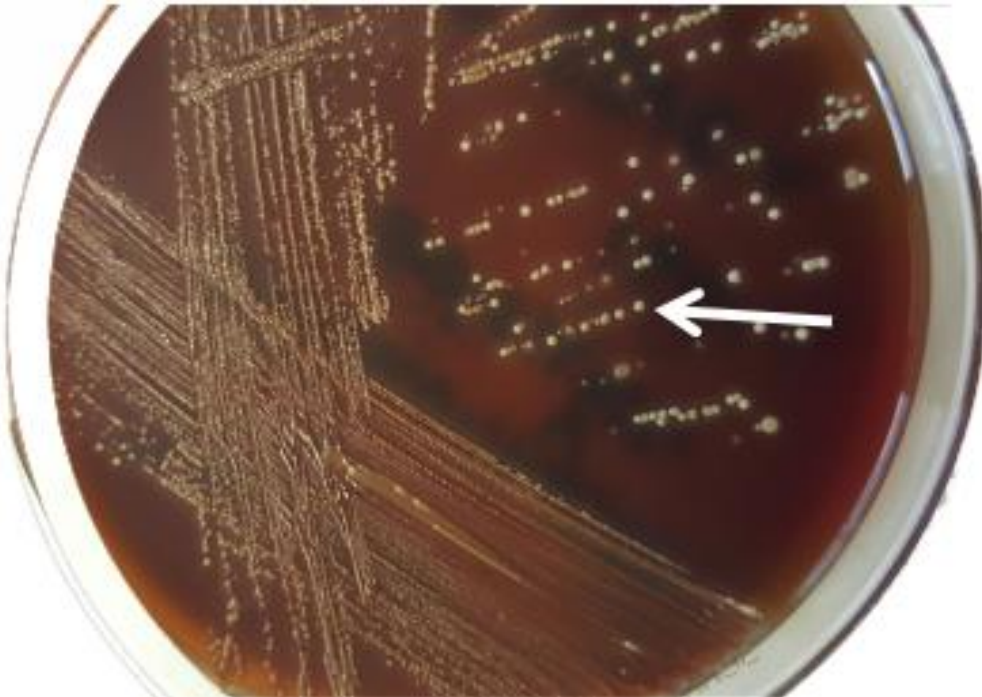


Figure 9: Anaerobic bacterial culture of a MRONJ sample. Actinomyces sp. grown as large whitish colonies are indicated by an arrow.

In this study we focused only bone sample culturing for microorganism (swap culture would be excluded) in which we had one hundred and thirty-six samples. Based on bone culture results, around 68% of the samples had positive microbiological findings (In our study, we count more than highly positive [3+ and 2+] as a positive result.) and we found around 1.25 positive Bacteria per sample (mean 1.25, SD=1.153). The most common microorganisms were mixed flora of the oral cavity (30.1%) followed by actinomyces (21.3%), streptococcus (16.9%), enterobacter group (15.4%) and miscellaneous group (13.2%).

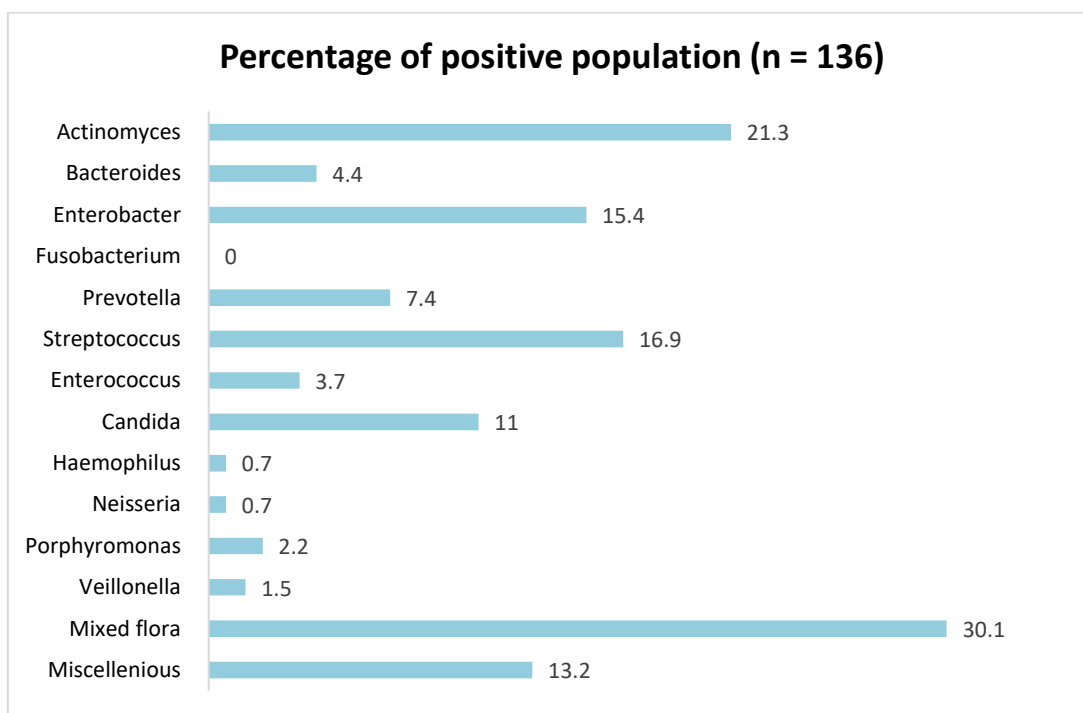


Figure 10: Microbiological profiling from bone cultures. Percentage of positive population (n = 136)

3.9 Small group comparison

Bacteria Profiling will be done in a small group to see if it has a different outcome in culture results.

3.9.1 Swap Group.

To eliminate an error due to different culture techniques we excluded a patient with swap test from the major sample group. Nevertheless we still have the results for small group comparison. The results showed five most common microorganism from the swap group: mixed flora of oral cavity, streptococcus, actinomyces, haemophilus and miscellaneous group. Haemophilus species presented instead of enterobacter group in bone culture report.

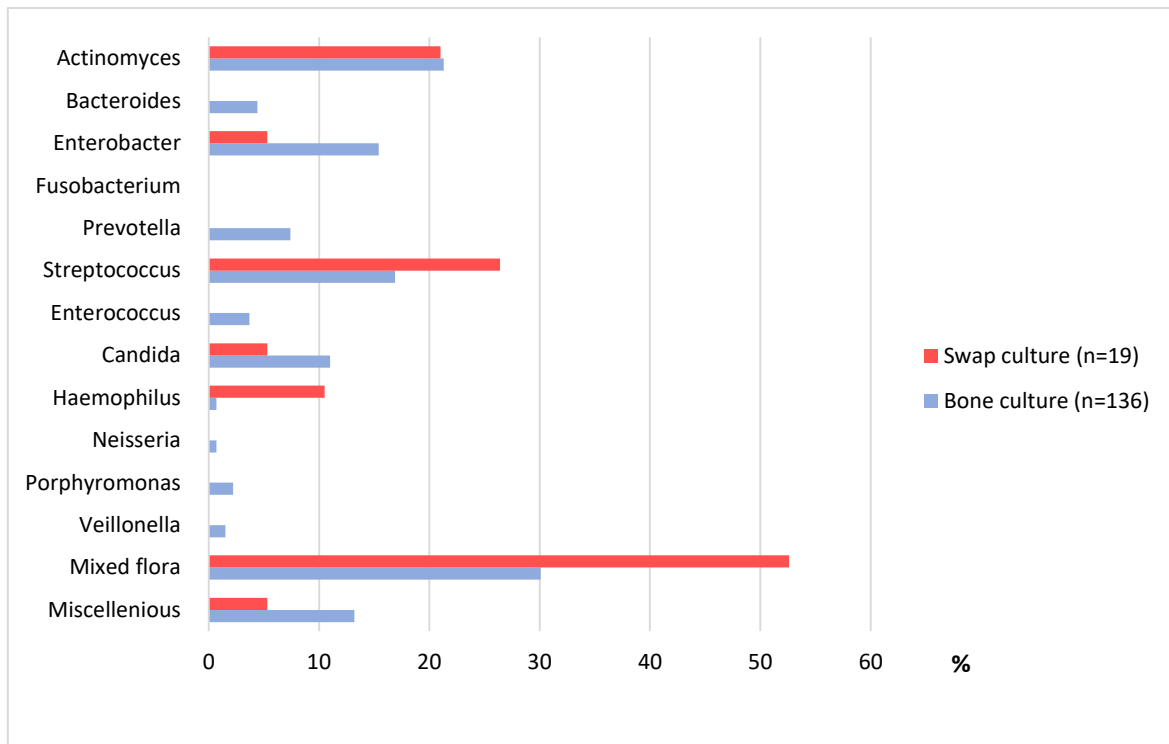


Figure 11: Microbiological bone culture profiling. Comparison between Swap culture gr. and Bone culture gr.

3.9.2 Chemotherapy Group

We divided patients in two groups with or without chemotherapy in order to see the difference in the profiling. Both groups presented mixed flora of the oral cavity followed by actinomyces, streptococcus, enterobacter group and miscellaneous group as a most common organism. However, chemo gr. shows numbers of candida species (13.9%) when non-chemo gr. has only (7.1%).

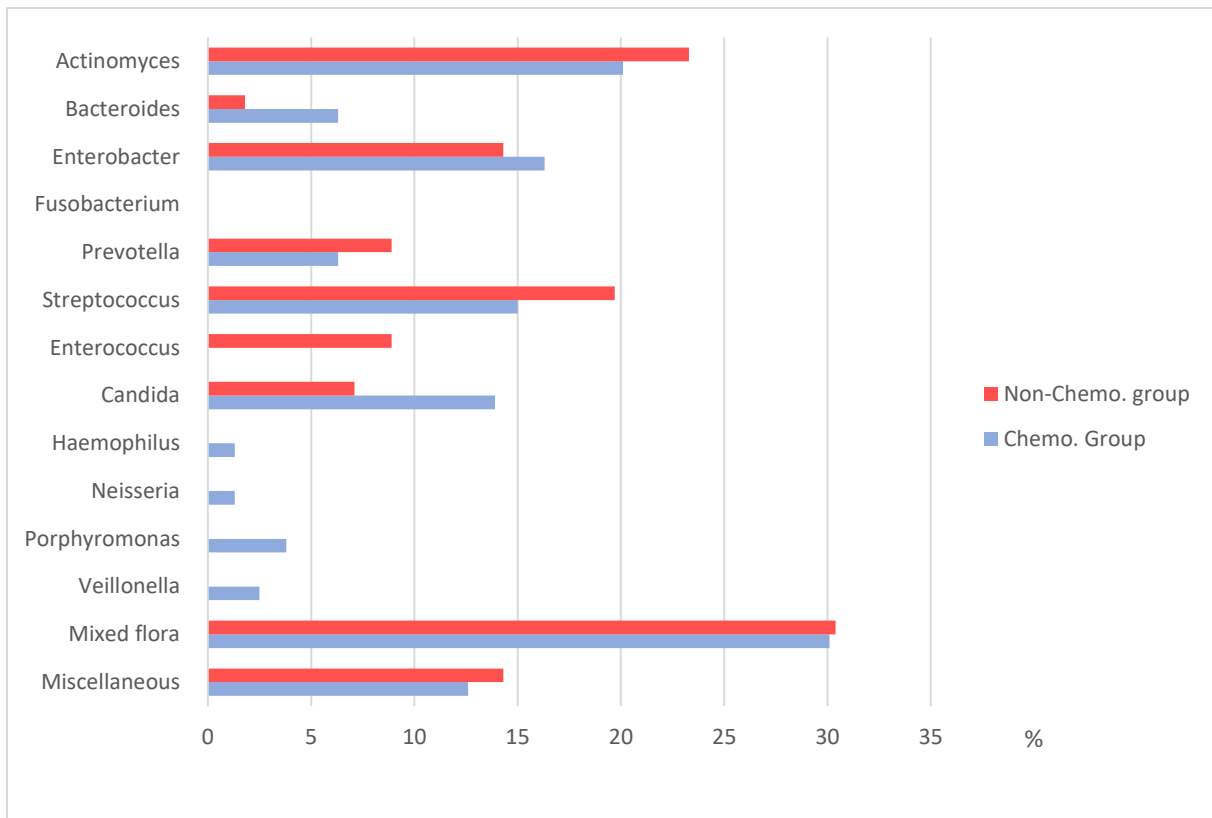


Figure 12: Microbiological bone culture profiling. Comparison between Non-Chemo gr. and Chemo gr.

3.9.3 Smoking group

Both patients groups with and without smoking habits show that mixed flora of oral cavity actinomyces, streptococcus and enterobacter group is the predominant group as is in the bone culture group.

Prevotella and enterococcus were absent in smoking gr. and candida spp. is more presented compare to non-smoking group (18% in smoking gr. and 8% in non-smoking gr.).

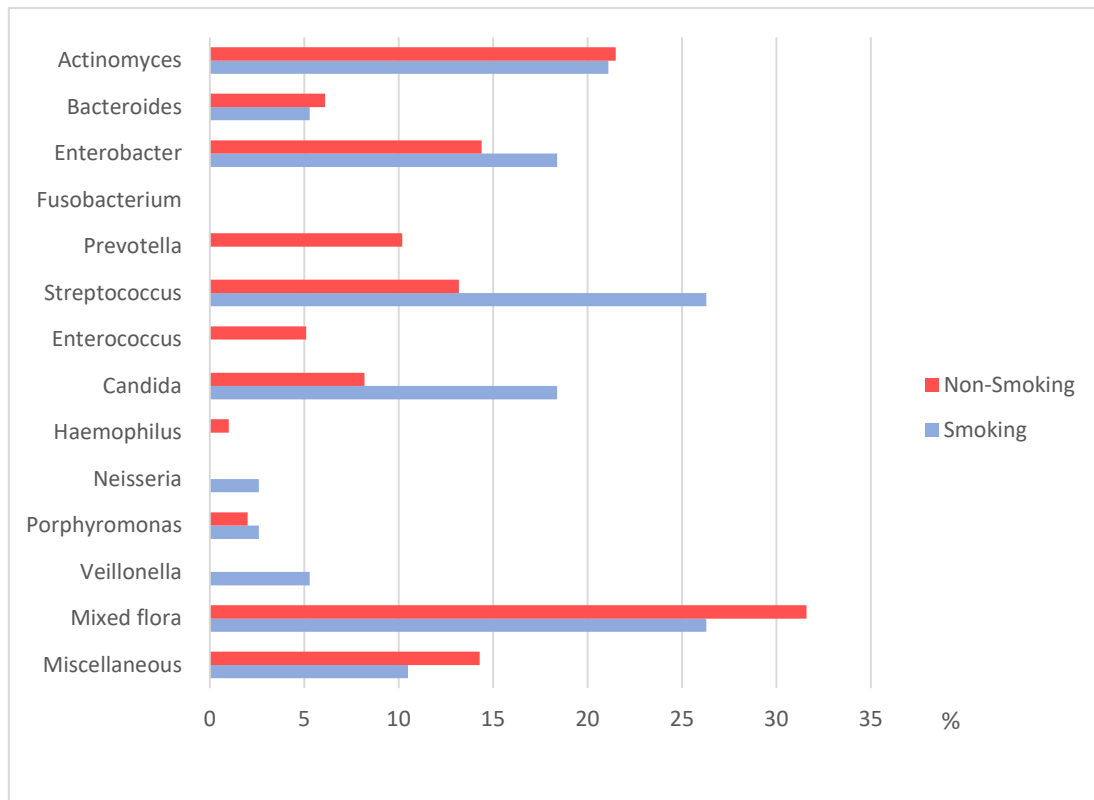


Figure 13: Microbiological bone culture profiling. Comparison between Non-smoking gr. and Smoking gr.

3.9.4 Steroid Group and Diabetes Group

There is not much difference in bacterial profiling of steroid and diabetes group.

Patient with and without steroid treatment.

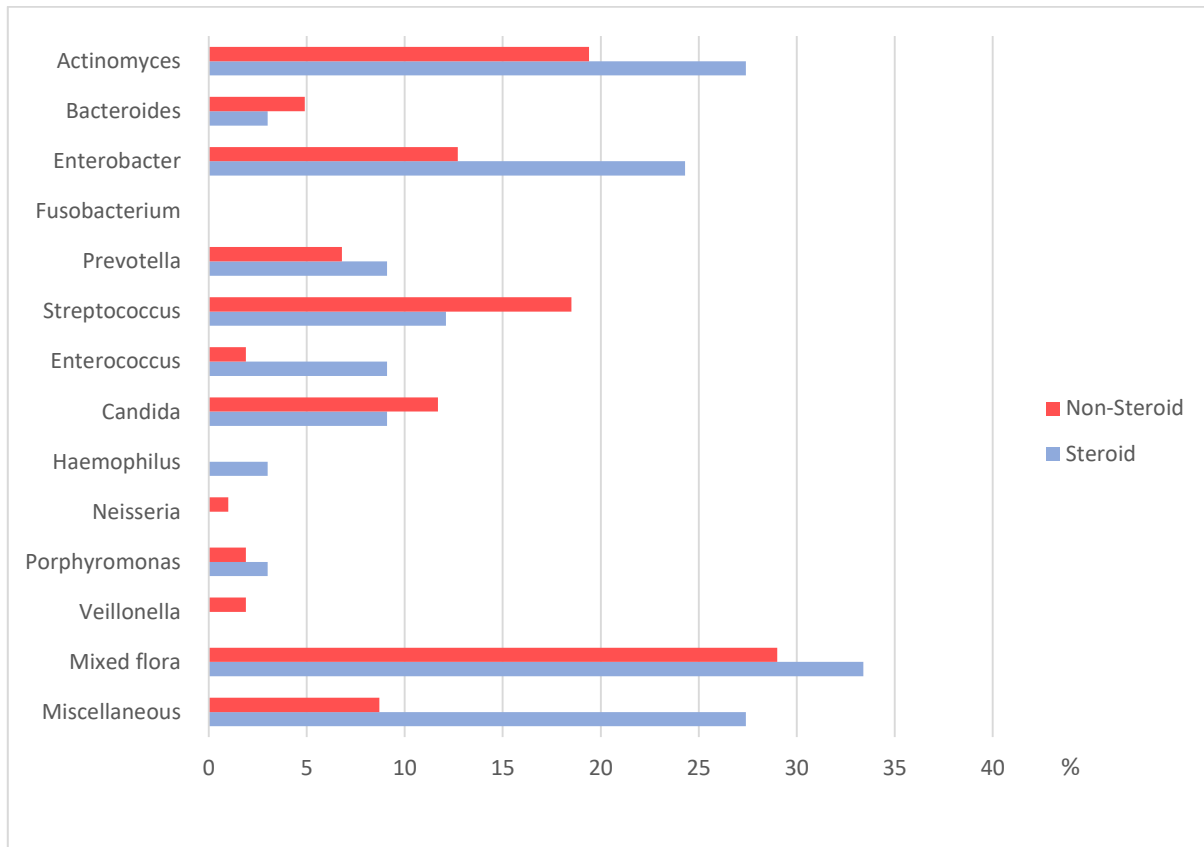


Figure 14: Microbiological bone culture profiling. Comparison between Non-steroid gr. VS Steroid gr.

Patient with and without diabetes.

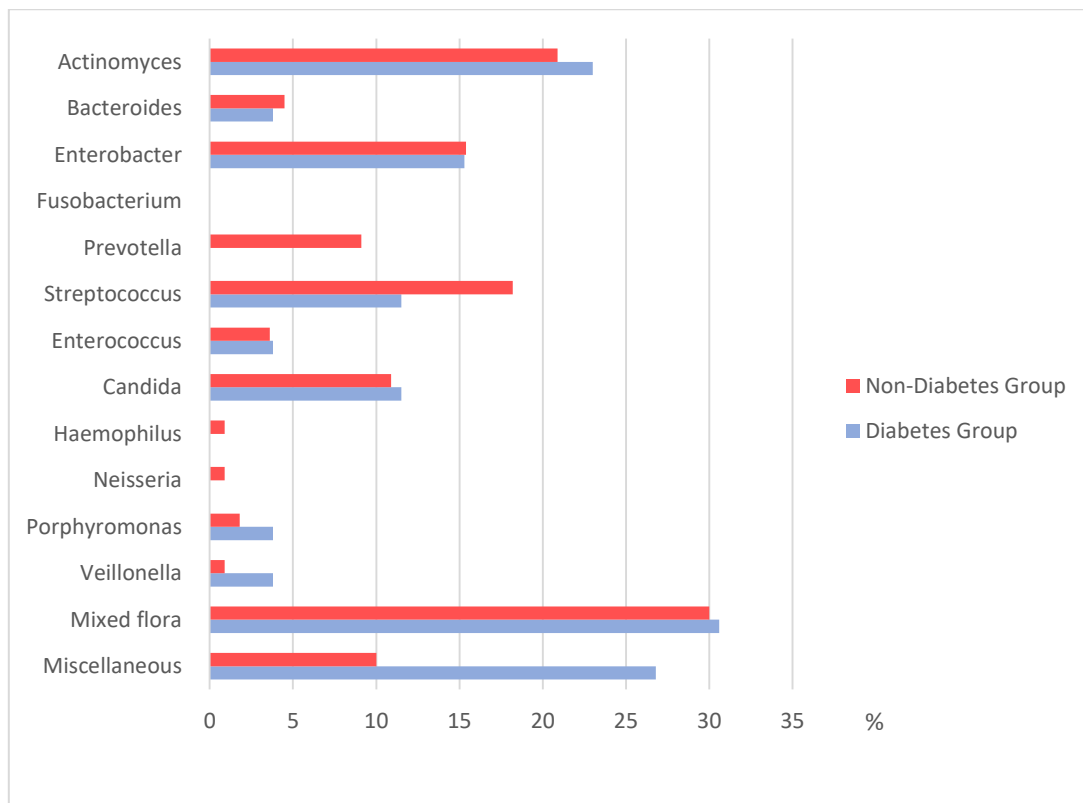


Figure 15: Microbiological bone culture profiling. Comparison between Non-diabetes gr. and Diabetes gr.

3.10 Actinomyces identification

Detection of *Actinomyces* sp. using a specific real-time PCR was performed on 83 patients (with the same specimen for bone cultures) and all were positive in some level. Fig 16 represents the results of 3 positive samples with distinct cycle threshold (Ct)-values indicating different numbers of *Actinomyces* sp. in the respective patient samples.

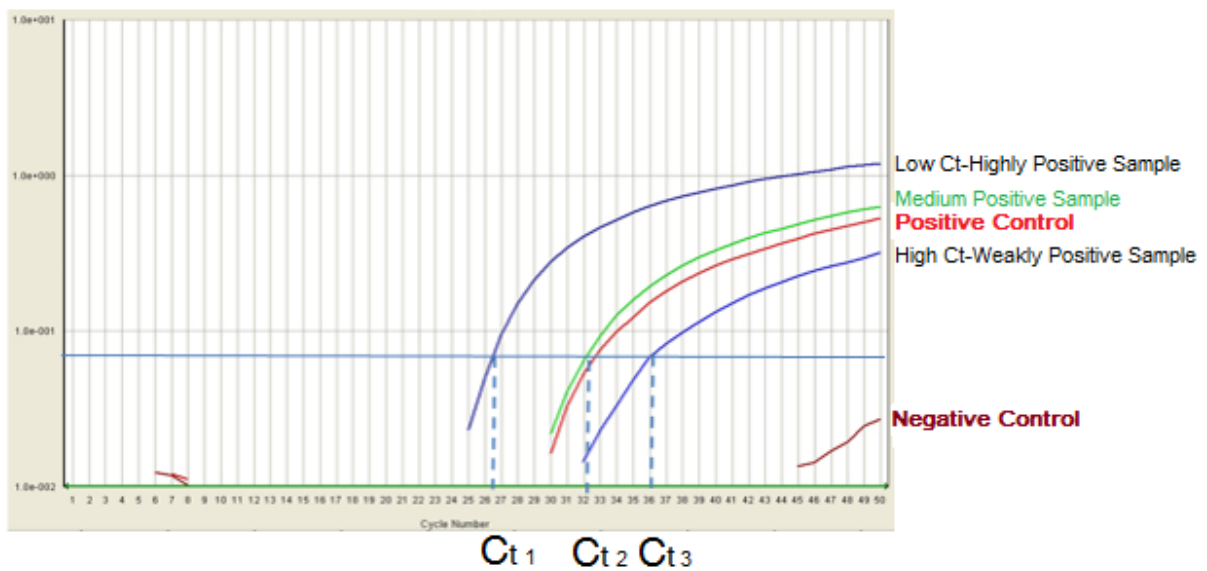


Figure 16: Detection of *Actinomyces* sp. using a specific real-time PCR. The diagram shows the results of positive samples with distinct cycle threshold (Ct)-values indicating different numbers of *Actinomyces* sp. in the respective patient samples.

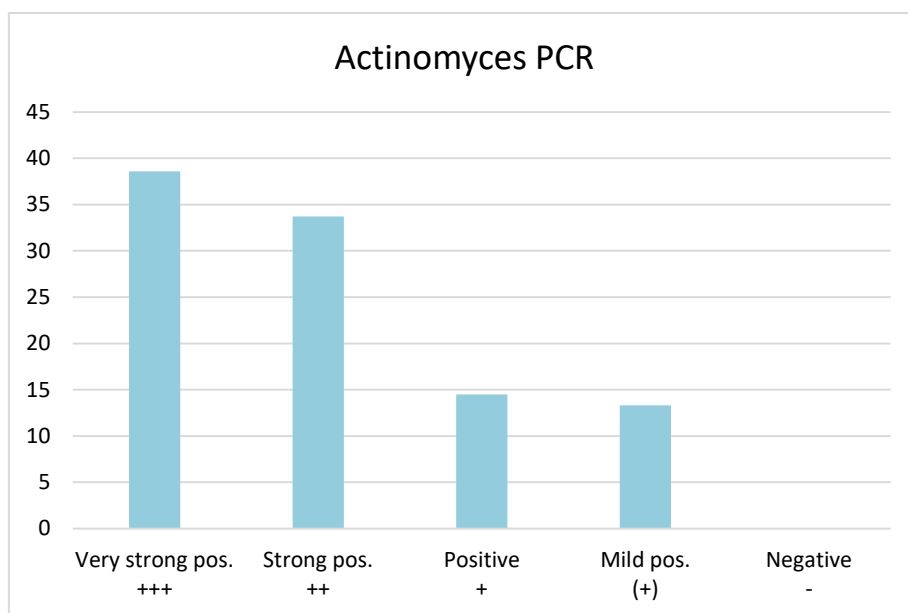


Figure 17: Actinomyces findings from real time PCR

3.10.1 Culturing vs PCR

In order to eliminate false positive results, we counted none of mild positive (+) and positive + PCR results and calculated them as negative findings similar to bone culture results.

Eighty-three patients had both bone culture and PCR for actinomyces results. Sixty of eighty three (72.3%) PCR test were positive while twenty three of eighty three (27.7%) had positive actinomyces culture results.

Twenty one of eighty three (25.3%) had both PCR and culture positive for actinomyces and thirty nine of eighty three (46.9%) had positive PCR but negative culture for actinomyces.

Table 9: Cross table defining Actinomyces finding between bone cultures and real time PCR

Culture for Act.	PCR for Act.		total
	positive	negative	
positive	21	2	23
negative	39	21	60
total	60	23	83

4 DISCUSSION

The objectives of this study were i) to identify microorganisms in MRONJ from bone sample biopsy, ii) focusing on Actinomyces detection by performing real time PCR, and iii) to investigate the clinical and anamnestic characteristics in the respective MRONJ patients.

4.1 Pathological-Microbiological study of MRONJ

4.1.1 Pathophysiology

The terminology MRONJ had been well recognised worldwide nowadays due to the increase in the prevalence of the disease. The pathogenesis of the disease raised many questions regarding the potential mechanisms underlying the pathophysiology [96]. Several mechanisms have also been proposed. However, none of them were able to explain why the jawbone is the exclusive target [97]. Microbial infection in the pathogenesis of MRONJ is debatable and not fully elucidated with few publications referring to the importance of infection through actinomyces as a component in the multifactorial disease [17, 29, 98].

4.1.1.1 Pathological findings

Most histopathological findings in our study show a necrotic bone pattern with inflammatory cell infiltration. Around three-fourths of the samples show bacterial colonization and one-third indicates filamentous form rod. These findings of the bone samples in our study were similar to previous studies [99]. Inflammation patterns with bacterial accumulation in the pathological reports support the infectious hypothesis and value a bacterial study. Actinomyces-like bacteria were found in this study in great numbers.

4.1.2 Microbial identification

We did not find many microorganisms reports of MRONJ in bone samples in previous studies. Sedghizadeh et al. in 2008 first [79] examined 4 samples under SEM and found bacterial morphotypes including fusobacterium, bacillus, actinomyces, staphylococcus, streptococcus, selenomonas, candida, and treponemes or spirochetes.

2012, Ji. et al. [29] performed a cohort study with 20 samples of MRONJ patients comparing antibiotics effect on bacterial finding. They described abundance of Firmicutes phylum (Streptococcus spp.) in patients that were treated with antibiotics. Wei. et al [30] likewise carried out molecular profiling on 6 MRONJ bone samples. Streptococcus, Eubacterium and Pseudoramibacter were reported as leading microorganisms. In 2014, Pushalkar et al [34] performed a cohort study on molecular profiling with 15 MRONJ samples of Parvimonas, Peptostreptococcus, Fusobacterium, Eubacterium, Dialister and Gemella. All previous studies had the same limitations of small subject sizes.

To our knowledge, this study is the first report with more than 30 MRONJ bone samples including 136 bone samples from 2003-2015. 69 species were found (appendix 3). It shows the variety of geniuses.

Most of the oral bacteria were found in this study. It indicated mixed flora of the oral cavity with (30.1%) Actinomyces spp (21.3%), Streptococcus spp (16.9%), and Enterobacter group (15.4%) being the most common microorganisms. Followed by Candida spp, Prevotella spp, Bacteroides spp and Enterococcus spp. These finding show a predominance of facultative anaerobe bacteria in our MRONJ lesion.

Some phylotypes of microorganism were unique to MRONJ more than other non-MRONJ infections in previous studies (Streptococcus, Eubacterium and Pseudoramibacter) [30]. Different from previous studies, there was the absence of Eubacterium spp. (rigid cell wall bacterial type) in this study.

These results confirm that microorganisms accumulate in the MRONJ lesions. We hope that these findings will benefit oral and maxillofacial surgeons, give information about microbiological aspects of MRONJ and may help to adjust antibiotic application, antiseptic techniques and surgical approaches in MRONJ patients.

4.1.2.1 Microbiological comparison of findings in subgroups

This study showed various bacterial findings in MRONJ subgroups. It showed not much difference in comparing MRONJ patients with and without chemotherapy, except that more species were found in the chemo group. On the other hand, patients with smoking habits show different results compared to non-smokers. The culture results show twice as much *Candida* species, *Streptococcus* species and *Neisseria* species in smoking group when compared to non-smoking group.

Chemotherapy treatment is a systemic factor that impacts the whole body. Other systemic subgroups such as diabetes and steroid intake also did not show a significant difference. From this finding, it could be implied that local factors had more influence than systemic ones.

Regarding the analysis of subgroups further studies with more specific control of subjects and other factors. The difference in microorganisms' findings could lead to an alternative antibiotic regimens treating MRONJ in some patients.

4.1.3 Actinomyces findings

Actinomyces species were present in most of the times in previous studies of MRONJ [29, 70, 80, 88, 89]. MRONJ had a former name of “*Actinomyces-osteonecrosis of the jaw*”

with high prevalence of actinomyces infection [92]. From the results of this thesis, we had 21.3% of population positive actinomyces culture. It was proven that actinomyces were highly prevalent in MRONJ patients which were consistent with a previous report on MRONJ bone samples [88, 89, 90, 91].

Actinomyces are hard to be cultured in vitro, also the transport to the lab could result in the damage of the specimen. Many actinomyces species die during culturing and their growth is inhibited by the presence of other microorganisms. However, DNA from dead organisms can still be detected by PCR methods [93].

Microbiological cultures were used as a traditional technique to identify actinomyces from bone samples. Anaerobic culturing was done in all 136 samples. However, these results were confirmed by PCR for 83 bone samples. The positive PCR results of the bone samples that were negative to culture (39 from 83 samples = 46.98 %) were attributed to the high sensitivity of the PCR compared to culture methods. These results show that PCR targeting the 16S rRNA region can be used to detect actinomyces in MRONJ bone samples.

From these results, we confirmed that PCR using 16S rRNA was useful in identifying actinomyces directly from bone samples. PCR targeting the 16S rRNA gene of the actinomyces is highly conserved within species of the same genus and is thus considered the new standard for classification and identification of bacteria as well as a reliable method for the distinction of species that are difficult to cultivate [100, 101]. PCR is superior to microbiological cultures in diagnosis of oral actinomyces as being highly sensitive and rapidly detecting actinomyces either dead or alive. Another advantage is that it quantifies DNA rather than viable organisms. However, culturing methods cannot detect non-viable bacteria [93].

In this study, we have confirmed the presence of microorganism especially actinomyces species in the bone samples but it is not clearly known whether osteonecrosis occurs before the infection of the necrotic lesion or if the infected lesion undergoes

osteonecrosis [102]. There are some evidences showing that infection is necessary for osteonecrosis with formation of a bacterial biofilm in the lesion [97, 103, 104] as the oral cavity is occupied by hundreds of bacterial species existing in the biofilm. When the patient immunity is decreased, those microorganisms show opportunistic infection such as actinomyces which are dominant pathogenic microorganisms detected at MRONJ by histopathological studies [99].

4.2 Patient characteristic, disease presentation, risk and initiation factors

4.2.1 Age, gender and underlying disease

Females had a prevalence to the disease compared to males. Advanced age and malignancy also have been mentioned, particularly in those with breast and prostate cancer [105]. In this study, we had 61% female patients with a mean age of 70.1 years. Around 90% of the patients had cancer as a primary disease and were therefore being treated with antiresorptive drugs. These results confirmed the information from previous studies.

However, we believe that these findings are influenced by the target group of antiresorptive drugs. Since the target-groups of antiresorptives are of advanced age and are predominately female. Besides, some studies recognized no statistically significant correlation between aging and MRONJ [106].

4.2.2 Comorbidities

Diabetes, smoking, chemotherapy and immune based disease (rheumatoid) were mentioned as relative risk factors. Correlations between MRONJ and other comorbidities such as chemotherapy and body radiation were also mentioned [106, 107]. In this study the sample

of population had diabetes mellitus (19.1%), chemotherapy (58.8%), and body radiation (44.9%), whereby 38 patients had smoking habits (27.9%) and 33 received steroids treatment (24.3).

It is known that elderly patients with comorbidities have a closer correlation to develop MRONJ. These comorbidities affect i) bone remodelling by microvascular ischemia and compromise wound healing as well as ii) impaired osteoblastic differentiation and function plus iii) induce additional immunosuppressive and antiangiogenic effects [108, 109]. In particular, smoking creates an environmental change in the oral cavity, which lowers the local immunity while Diabetes deters the cellular immune system. Therefore, we suspect that both factors have a role in the development MRONJ.

4.2.3 Preceding events

Tooth extraction and surgical trauma are noted as preceding events [52, 53, 106]. It has been reported that there are up to 60% MRONJ cases occurred after tooth extractions. Still, spontaneous MRONJ also has 25%. In this study, dental extractions were involved 53.7% with lesions and 11.8% of the patients received other dentoalveolar surgeries, equally 11.8% received periodontal treatment and 4.4% developed denture pressure sores. Roughly 18.4% reported no intervention in the lesion area.

Although no consensus has been reached regarding the mechanism of MRONJ, in the present study, MRONJ developed either spontaneously or after dentoalveolar reasons such as tooth extractions, periodontal disease and denture pressure sore trauma.

Some studies proved that tooth extractions and dentoalveolar surgical procedures aim treating and curing local infections can even lead to a decreased risk for the development of MRONJ [62, 110]. Local infections were treated and overcome by the removal of infected teeth and suspicious bone lesions, by antibiotic treatment and mucosal coverage of the

extraction wounds, thereby protecting the extraction sockets from bacterial ingrowth after extraction [111].

4.2.4 Antiresorptive drugs

Antiresorptive agents were regarded as a major risk factor for the development of MRONJ lesions. This study has corroborated that MRONJ is more frequent in subjects with intravenous bisphosphonates than in oral regimen [112]. Zoledronate was the most consumed and also the highest potency intravenous bisphosphonate (Figure 2). 80% of our population receive zoledronate or a combination. The cumulative risk of developing MRONJ was significantly increased in patients receiving zoledronic acid [117]. However, our result shows that MRONJ can also occur when denosumab is subjected subcutaneously.

4.2.5 Disease presentation and Localisation

The disease presentation was described in diagnosis and classification criteria. The classic clinical presentation of MRONJ is bone exposure with signs of infection, swelling and a purulent discharge [105]. In this study, the symptoms of inflammation, pain and exposed bone were present in the major part of the population. Signs of infection were also noted in previous reports. We believe infectious process is playing a major role in MRONJ as we will discuss in the following sections.

Results of this study show that the majority of cases were in the stage II classification which is comparable to findings in other studies [113, 114]. MRONJ lesions occurred in the mandible (73.5%) twice as much as in the maxilla (31.5%) which was also in accordance with previous studies [50, 61].

4.2.6 Prevention and Prophylaxis

AAOMS position paper 2014 [4] has recommended a consultation with an appropriate dental professional before initiating an antiresorptive or antiangiogenic drug therapy.

Dimopoulos et al [118] and Vandone et al [119] found a statistically significant decrease in the incidence of osteonecrosis in patients who received preventive dental care before initiating drug treatment. There is a reasonable support that not only a reduced incidence of ONJ, but also increases the benefit that all patients receive optimum oral health from early screening and appropriate dental care [120, 121, 122, 123].

Only 4 of the 136 MRONJ cases proved visited dentist or oral maxillofacial surgeon before antiresorptive therapy. This number shows a lack of MRONJ awareness among medication providers. One of our thesis objectives is to point out the infection aspect of MRONJ. As one of the most important factors, local infection should be eradicated before antiresortive therapy.

To examine all risk factors, it is beneficial in most cases when encountered with a new disease. MRONJ is special in particular because a decade after the pathophysiology and even terminology are still indefinite. Risk factors and all the relevant factors may not cause MRONJ themselves. However, keeping and updating this information will benefit in risk assessment process in treatment and prevention strategies.

4.3 Limitation

The limitations of this study are that:

- no control group of untreated with antibiotic or treated with antibiotic without MRONJ patients was considered.
- no non-MRONJ patients were characterized for bacterial species.
- no appropriated statistic comparison in subgroup analysis.
- the number of patients were reduced from 209 to 136 due to the incomplete records or absence of histopathological, microbiological or PCR diagnosis.

5 CONCLUSION

MRONJ can reduce patient's quality of life and may produce a significant morbidity due to impairment of chewing, swallowing and speaking as well as deterioration of facial aesthetics. Thus, it is of tremendous importance to treat those patients to adequately eliminate pain, control infection of soft and hard tissue and eradicate bone exposure [115]. Information might be useful in assisting surgeons in making suitable decisions on the treatment modality of the disease based on the hypothesis that infection maybe the most important factor negatively influencing the onset and progression of MRONJ.

The pathogenesis of MRONJ had raised many questions regarding the potential mechanisms underlying the pathophysiology with special attention to the role of microbial infection. Facultative anaerobe bacteria governing by Actinomyces, Streptococcus, and Enterobacter group were found as the highest frequency of microorganisms in 136 bone culture samples. The PCR results showed that Actinomyces were the most frequent microorganisms in the disease. However, this does not certainly lead to the pathogenic disease. PCR was found to be the most reliable method in the detection of these microorganisms.

6 SUMMARY

We hypothesized that local infection plays a critical role in the pathogenesis of medication-related osteonecrosis of the jaw (MRONJ). Recent developments in molecular methods have revolutionized new approaches for the rapid detection of microorganisms including those difficult to culture. The aim of our study is to identify the bacterial profiles in MRONJ by microbiological culture and polymerase chain reactions (PCR). A retrospective analysis was performed on MRONJ patients from 2003 to 2015 where the bacterial profile from MRONJ bone samples was determined using microbiological culture and PCR. One hundred and thirty six patients fulfilled the inclusion criteria with mean age of 70.1 ± 8.83 years. The mandible was more commonly affected than the maxilla. Tooth extraction was the frequent triggering factor. Breast cancer was the primary cause for administration and intravenous bisphosphonates were the most commonly administered antiresorptive drugs. The majority of patients were classified as stage 2. Posterior teeth were most commonly affected. Based on bone culture results, the most common microorganisms were both actinomyces and mixed oral flora. PCR confirmed the presence of undetected actinomyces in 83 patients. The data resulting from this study suggest that PCR might be an innovative method for detection of microorganisms difficult to culture better than using traditional microbiological techniques.

ZUSAMMENFASSUNG

Nach neuesten Erkenntnissen spielen lokale Infektionen bei der Pathogenese der Medikamenten-assoziierten Osteonekrose der Kiefer (MRONJ) eine entscheidende Rolle. Mit der Entstehung und mit der Manifestation von Infektionen sind Alterationen des Keimspektrums von der physiologischen Mundflora hin zur Etablierung einzelner Keimspezies zu erkennen. Die Verbesserung der Sensivität von molekular-diagnostischen Modalitäten eröffnet neue Optionen für den selektiven Nachweis von Mikroorganismen, die im Zuge einer derartigen Verschiebung vermehrt auftreten.

Das Ziel dieser Studie war es, die Bakterienprofile, die beim Krankheitsbild MRONJ vorliegen, durch mikrobiologische Kultur und Polymerase Kettenreaktionen (PCR) zu identifizieren und charakterisieren.

Es wurde in einem retrospektiven Studiendesign das Erregerprofil von Patienten bestimmt, die an einer MRONJ erkrankt waren und sich im Zeitraum von 2003 bis 2015 in der Klinik und Poliklinik für Mund-, Kiefer- und Gesichtschirurgie der LMU München in Behandlung befanden. Hierfür wurden an den gewonnenen Knochenbiopsien durch mikrobiologische Kultur und PCR das Vorkommen von bestimmten Bakterienarten untersucht.

Die untersuchte Kohorte umfasste 136 Patienten in einem Durchschnittsalter von 70,1 ± 8,83 Jahren. Der Unterkiefer war bei diesen Patienten häufiger betroffen als der Oberkiefer. Zahnextraktionen in Kombination mit in der Vergangenheit stattgehabter intravenöser Applikation von Bisphosphonaten gingen der MRONJ häufig als induzierende Faktoren voraus. Bisphosphonate wurden hierbei häufig therapeutisch bei Patienten eingesetzt, die unter einem skelettal metastasierten Mammakarzinom litten. Der Großteil der Patienten wurde in das Stadium 2 (AAOMS 2014) eingestuft.

Basierend auf den mikro- und molekularbiologischen Untersuchungen wurden Actinomyzeten als am häufigsten vorkommende Bakterien identifiziert. Dabei komplettierte die PCR, die üblicherweise eingesetzten Nachweismethodiken. Im Vergleich zu diesen konnte durch den Einsatz der PCR bei 83 Patienten eine Besiedelung mit Actinomyzeten nachgewiesen werden, die in der mikrobiologischen Kultur nicht erkannt wurden.

Die PCR stellt eine die üblichen mikrobiologischen Untersuchungen komplettierende Methode zum selektiven Nachweis von Mikroorganismen dar, die aufgrund ihrer geringen Anzahl und schwierigen Kultivierungsvoraussetzungen mit herkömmlicher mikrobiologischer Diagnostik nicht nachzuweisen sein können.

7 REFERENCES

- [1] Licata AA. Discovery, clinical development, and therapeutic uses of bisphosphonates. *Ann Pharmacother.* 2005;39:668-77.
- [2] Drake MT, Clarke BL, Khosla S. Bisphosphonates: mechanism of action and role in clinical practice. *Mayo Clin Proc.* 2008;83(9):1032-45.
- [3] Marx RE. Pamidronate (Aredia) and zoledronate (Zometa) induced avascular necrosis of the jaws: a growing epidemic. *J Oral Maxillofac Surg.* 2003;61(9):1115-7.
- [4] Ruggiero SL, Dodson TB, Fantasia J, Goodday R, Aghaloo T, Mehrotra B, et al. American Association of Oral and Maxillofacial Surgeons position paper on medication-related osteonecrosis of the jaw--2014 update. *J Oral Maxillofac Surg.* 2014;72:1938-56.
- [5] Ruggiero SL, Dodson TB, Assael LA, Landesberg R, Marx RE, Mehrotra B; Task Force on Bisphosphonate-Related Osteonecrosis of the Jaws, American Association of Oral and Maxillofacial Surgeons. American Association of Oral and Maxillofacial Surgeons position paper on bisphosphonate-related osteonecrosis of the jaw - 2009 update. *Aust Endod J.* 2009;35(3):119-30.
- [6] Russell RG, Mühlbauer RC, Bisaz S, Williams DA, Fleisch H. The influence of pyrophosphate, condensed phosphates, phosphonates and other phosphate compounds on the dissolution of hydroxyapatite in vitro and on bone resorption induced by parathyroid hormone in tissue culture and in thyroparathyroidectomised rats. *Calcif Tissue Res.* 1970;6(3):183-96.
- [7] Delmas PD, Balena R, Confravreux E, Hardouin C, Hardy P, Bremond A. Bisphosphonate risedronate prevents bone loss in women with artificial menopause due to chemotherapy of breast cancer: a double-blind, placebo-controlled study. *J Clin Oncol.* 1997;15(3):955-62.
- [8] Delmas PD. The use of bisphosphonates in the treatment of osteoporosis. *Curr Opin Rheumatol.* 2005;17(4):462-6.

- [9] Miller PD, Bolognese MA, Lewiecki EM, McClung MR, Ding B, Austin M, Liu Y, San Martin J; Amg Bone Loss Study Group. Effect of denosumab on bone density and turnover in postmenopausal women with low bone mass after long-term continued, discontinued, and restarting of therapy: a randomized blinded phase 2 clinical trial. *Bone*. 2008;43(2):222-9.
- [10] Ruggiero SL1, Mehrotra B, Rosenberg TJ, Engroff SL. Osteonecrosis of the jaws associated with the use of bisphosphonates: a review of 63 cases. *J Oral Maxillofac Surg*. 2004;62(5):527-34.
- [11] Roelofs AJ, Thompson K, Gordon S, Rogers MJ. Molecular mechanisms of action of bisphosphonates: current status. *Clin Cancer Res*. 2006;12(20 Pt 2):6222s-6230s.
- [12] Russell RG, Watts NB, Ebtino FH, Rogers MJ. Mechanisms of action of bisphosphonates: similarities and differences and their potential influence on clinical efficacy. *Osteoporos Int*. 2008;19(6):733-59.
- [13] Baron R. Osteoporosis in 2011: Osteoporosis therapy--dawn of the post-bisphosphonate era. *Nat Rev Endocrinol*. 2011;8(2):76-8.
- [14] Lacey DL, Boyle WJ, Simonet WS, Kostenuik PJ, Dougall WC, Sullivan JK, San Martin J, Dansey R. Bench to bedside: elucidation of the OPG-RANK-RANKL pathway and the development of denosumab. *Nat Rev Drug Discov*. 2012;11(5):401-19.
- [15] Suresh E, Abrahamsen B. Denosumab: a novel antiresorptive drug for osteoporosis. *Cleve Clin J Med*. 2015;82(2):105-14.
- [16] Reid IR, Miller P, Lyles K, Fraser W, Brown JP, Saidi Y, Mesenbrink P, Su G, Pak J, Zelenakas K, Luchi M, Richardson P, Hosking D. Comparison of a single infusion of zoledronic acid with risedronate for Paget's disease. *N Engl J Med*. 2005;353(9):898-908.
- [17] Allen MR, Burr DB. The pathogenesis of bisphosphonate-related osteonecrosis of the jaw: so many hypotheses, so few data. *J Oral Maxillofac Surg*. 2009;67(5 Suppl):61-70.

- [18] Landesberg R, Woo V, Cremers S, Cozin M, Marolt D, Vunjak-Novakovic G, Kousteni S, Raghavan S. Potential pathophysiological mechanisms in osteonecrosis of the jaw. *Ann N Y Acad Sci.* 2011;1218:62-79.
- [19] Yamashita J, McCauley LK. Antiresorptives and osteonecrosis of the jaw. *J Evid Based Dent Pract.* 2012;12(3 Suppl):233-47.
- [20] Ziebart T, Pabst A, Klein MO, Kämmerer P, Gauss L, Brüllmann D, Al-Nawas B, Walter C. Bisphosphonates: restrictions for vasculogenesis and angiogenesis: inhibition of cell function of endothelial progenitor cells and mature endothelial cells in vitro. *Clin Oral Investig.* 2011;15(1):105-11.
- [21] Tsai SH, Huang PH, Chang WC, Tsai HY, Lin CP, Leu HB, Wu TC, Chen JW, Lin SJ. Zoledronate inhibits ischemia-induced neovascularization by impairing the mobilization and function of endothelial progenitor cells. *PLoS One.* 2012;7(7):e41065.
- [22] Bi Y, Gao Y, Ehrchiou D, Cao C, Kikuri T, Le A, Shi S, Zhang L. Bisphosphonates cause osteonecrosis of the jaw-like disease in mice. *Am J Pathol.* 2010;177(1):280-90.
- [23] Wood J, Bonjean K, Ruetz S, Bellahcène A, Devy L, Foidart JM, Castronovo V, Green JR. Novel antiangiogenic effects of the bisphosphonate compound zoledronic acid. *J Pharmacol Exp Ther.* 2002;302(3):1055-61.
- [24] Reid IR, Bolland MJ, Grey AB. Is bisphosphonate-associated osteonecrosis of the jaw caused by soft tissue toxicity? *Bone.* 2007;41(3):318-20.
- [25] Landesberg R, Cozin M, Cremers S, Woo V, Kousteni S, Sinha S, Garrett-Sinha L, Raghavan S. Inhibition of oral mucosal cell wound healing by bisphosphonates. *J Oral Maxillofac Surg.* 2008;66(5):839-47.
- [26] Moreira MS1, Katayama E, Bombana AC, Marques MM. Cytotoxicity analysis of alendronate on cultured endothelial cells and subcutaneous tissue. a pilot study. *Dent Traumatol.* 2005;21(6):329-35.

- [27] Reszka AA, Halasy-Nagy J, Rodan GA. Nitrogen-bisphosphonates block retinoblastoma phosphorylation and cell growth by inhibiting the cholesterol biosynthetic pathway in a keratinocyte model for esophageal irritation. *Mol Pharmacol*. 2001;59(2):193-202.
- [28] Egan PJ, Carding SR. Downmodulation of the inflammatory response to bacterial infection by gammadelta T cells cytotoxic for activated macrophages. *J Exp Med*. 2000;191(12):2145-58.
- [29] Ji X, Pushalkar S, Li Y, Glickman R, Fleisher K, Saxena D. Antibiotic effects on bacterial profile in osteonecrosis of the jaw. *Oral Diseases*. 2012;18:85-95.
- [30] Wei X, Pushalkar S, Estilo C, Wong C, Farooki A, Fornier M, Bohle G, Huryn J, Li Y, Doty S, Saxena D. Molecular profiling of oral microbiota in jawbone samples of bisphosphonate-related osteonecrosis of the jaw. *Oral Dis*. 2012;18(6):602-12.
- [31] Kos M, Junka A, Smutnicka D, Bartoszewicz M, Kurzynowski T, Gluza K. Pamidronate enhances bacterial adhesion to bone hydroxyapatite. Another puzzle in the pathology of bisphosphonate-related osteonecrosis of the jaw? *J Oral Maxillofac Surg*. 2013;71(6):1010-6.
- [32] Ganguli A, Steward C, Butler SL, Philips GJ, Meikle ST, Lloyd AW, Grant MH. Bacterial adhesion to bisphosphonate coated hydroxyapatite. *J Mater Sci Mater Med*. 2005;16(4):283-7.
- [33] Kos M1, Brusco D, Kuebler J, Engelke W. Clinical comparison of patients with osteonecrosis of the jaws, with and without a history of bisphosphonates administration. *Int J Oral Maxillofac Surg*. 2010;39(11):1097-102.
- [34] Pushalkar S, Li X, Kurago Z, Ramanathapuram LV, Matsumura S, Fleisher KE, et al. Oral microbiota and host innate immune response in bisphosphonate-related osteonecrosis of the jaw. *Int J Oral Sci*. 2014;6(4):219-26.

- [35] Tsurushima H, Kokuryo S, Sakaguchi O, Tanaka J, Tominaga K. Bacterial promotion of bisphosphonate-induced osteonecrosis in Wistar rats. *Int J Oral Maxillofac Surg*. 2013;42(11):1481-7.
- [36] Sakaguchi O, Kokuryo S, Tsurushima H, Tanaka J, Habu M, Uehara M, Nishihara T, Tominaga K. Lipopolysaccharide aggravates bisphosphonate-induced osteonecrosis in rats. *Int J Oral Maxillofac Surg*. 2015;44(4):528-34.
- [37] Otto S, Hafner S, Mast G, Tischer T, Volkmer E, Schieker M, et al. Bisphosphonate-related osteonecrosis of the jaw: is pH the missing part in the pathogenesis puzzle? *J Oral Maxillofac Surg* 2010;68:1158-61.
- [38] Ikebe T. Pathophysiology of BRONJ: Drug-related osteoclastic disease of the jaw. *Oral Science Internatl*. 2013; 10(1):1–8.
- [39] Wimalawansa SJ. Bisphosphonate-associated osteomyelitis of the jaw: guidelines for practicing clinicians. *Endocr Pract*. 2008;14(9):1150-68.
- [40] Gallego L, Junquera L. Consequence of therapy discontinuation in bisphosphonate-associated osteonecrosis of the jaws. *Br J Oral Maxillofac Surg*. 2009;47(1):67-8.
- [41] Bamias A, Kastiritis E, Bamia C, Moulopoulos LA, Melakopoulos I, Bozas G, et al. Osteonecrosis of the jaw in cancer after treatment with bisphosphonates: incidence and risk factors. *J Clin Oncol*. 2005;23:8580-7.
- [42] Woo SB, Hellstein JW, Kalmar JR. Narrative [corrected] review: bisphosphonates and osteonecrosis of the jaws. *Ann Intern Med*. 2006;144(10):753-61.
- [43] Saad F, Mulders P. Bisphosphonate anticancer activity in prostate cancer and other genitourinary cancers. *Anticancer Agents Med Chem*. 2012;12(2):129-36.
- [44] Tsao C, Darby I, Ebeling PR, Walsh K, O'Brien-Simpson N, Reynolds E, Borromeo G. Oral health risk factors for bisphosphonate-associated jaw osteonecrosis. *J Oral Maxillofac Surg*. 2013;71(8):1360-6.

- [45] Tosi P, Zamagni E, Cangini D, Tacchetti P, Di Raimondo F, Catalano L, D'Arco A, Ronconi S, Cellini C, Offidani M, Perrone G, Ceccolini M, Brioli A, Tura S, Baccarani M, Cavo M. Osteonecrosis of the jaws in newly diagnosed multiple myeloma patients treated with zoledronic acid and thalidomide-dexamethasone. *Blood*. 2006;108(12):3951-2
- [46] Wessel JH, Dodson TB, Zavras AI. See comment in PubMed Commons below Zoledronate, smoking, and obesity are strong risk factors for osteonecrosis of the jaw: a case-control study. *J Oral Maxillofac Surg*. 2008;66(4):625-31.
- [47] Kyrgidis A, Andreadis C. Clinical characterization might help in preventing osteonecrosis of the jaw. *Clin Cancer Res*. 2008;14(24):8321.
- [48] Hokugo A, Christensen R, Chung EM, Sung EC, Felsenfeld AL, Sayre JW, Garrett N, Adams JS, Nishimura I. Increased prevalence of bisphosphonate-related osteonecrosis of the jaw with vitamin D deficiency in rats. *J Bone Miner Res*. 2010;25(6):1337-49.
- [49] Song Z1, Dong W, Yin L, Liu J, Sun H, Qi M. [Effect of thalidomide on development of bisphosphonate-related osteonecrosis of the jaws in rats]. *Nan Fang Yi Ke Da Xue Xue Bao*. 2015;35(8):1084-9.
- [50] Thumbigere-Math V, Sabino MC, Gopalakrishnan R, Huckabay S, Dudek AZ, Basu S, Hughes PJ, Michalowicz BS, Leach JW, Swenson KK, Swift JQ, Adkinson C, Basi DL. Bisphosphonate-related osteonecrosis of the jaw: clinical features, risk factors, management, and treatment outcomes of 26 patients. *J Oral Maxillofac Surg*. 2009;67(9):1904-13.
- [51] Nisi M, La Ferla F, Karapetsa D, Gennai S, Miccoli M, Baggiani A, Graziani F, Gabriele M. Risk factors influencing BRONJ staging in patients receiving intravenous bisphosphonates: a multivariate analysis. *Int J Oral Maxillofac Surg*. 2015;44(5):586-91.
- [52] Marx RE, Sawatari Y, Fortin M, Broumand V. Bisphosphonate-induced exposed bone (osteonecrosis/osteopetrosis) of the jaws: risk factors, recognition, prevention, and treatment. *J Oral Maxillofac Surg*. 2005;63(11):1567-75.

- [53] Marx RE, Cillo JE Jr, Ulloa JJ. Oral bisphosphonate-induced osteonecrosis: risk factors, prediction of risk using serum CTX testing, prevention, and treatment. *J Oral Maxillofac Surg.* 2007;65(12):2397-410.
- [54] Migliorati CA, Epstein JB, Abt E, Berenson JR. Osteonecrosis of the jaw and bisphosphonates in cancer: a narrative review. *Nat Rev Endocrinol.* 2011;7(1):34-42.
- [55] Li CL, Seneviratne CJ, Huo L, Lu WW, Zheng LW. Impact of *Actinomyces naeslundii* on bisphosphonate-related osteonecrosis of the jaws in ovariectomized rats with periodontitis. *J Craniomaxillofac Surg.* 2015 Oct;43(8):1662-9
- [56] Junquera L, Gallego L. Nonexposed bisphosphonate-related osteonecrosis of the jaws: another clinical variant? *J Oral Maxillofac Surg.* 2008;66(7):1516-7.
- [57] Hutchinson M, O'Ryan F, Chavez V, Lathon PV, Sanchez G, Hatcher DC, Indresano AT, Lo JC. Radiographic findings in bisphosphonate-treated patients with stage 0 disease in the absence of bone exposure. *J Oral Maxillofac Surg.* 2010;68(9):2232-40.
- [58] Aghaloo TL, Dry SM, Mallya S, Tetradis S. Stage 0 osteonecrosis of the jaw in a patient on denosumab. *J Oral Maxillofac Surg.* 2014;72(4):702-16
- [59] Ikeda T, Kuraguchi J, Kogashiwa Y, Yokoi H, Satomi T, Kohno N. Successful treatment of bisphosphonate-related osteonecrosis of the jaw (BRONJ) patients with sitafloxacin: new strategies for the treatment of BRONJ. *Bone.* 2015;73:217-22.
- [60] Ficarra G, Beninati F, Rubino I, Vannucchi A, Longo G, Tonelli P, Pini Prato G. Osteonecrosis of the jaws in periodontal patients with a history of bisphosphonates treatment. *J Clin Periodontol.* 2005;32(11):1123-8.
- [61] Boonyapakorn T, Schirmer I, Reichart PA, Sturm I, Massenkeil G. Bisphosphonate-induced osteonecrosis of the jaws: prospective study of 80 patients with multiple myeloma and other malignancies. *Oral Oncol.* 2008;44:857-69.

- [62] Otto S, Tröltzsch M, Jambrovic V, Panya S, Probst F, Ristow O, Ehrenfeld M, Pautke C. Tooth extraction in patients receiving oral or intravenous bisphosphonate administration: A trigger for BRONJ development? *J Craniomaxillofac Surg*. 2015;43(6):847-54.
- [63] Weinstein RS, Roberson PK, Manolagas SC. Giant osteoclast formation and long-term oral bisphosphonate therapy. *N Engl J Med*. 2009;360(1):53-62.
- [64] Marx RE, Tursun R. Suppurative osteomyelitis, bisphosphonate induced osteonecrosis, osteoradionecrosis: a blinded histopathologic comparison and its implications for the mechanism of each disease. *Int J Oral Maxillofac Surg*. 2012;41(3):283-9.
- [65] Bagan JV, Murillo J, Jimenez Y, Poveda R, Milian MA, Sanchis JM, Silvestre FJ, Scully C. Avascular jaw osteonecrosis in association with cancer chemotherapy: series of 10 cases. *J Oral Pathol Med*. 2005;34(2):120-3.
- [66] Ali SM, Esteva FJ, Hortobagyi G, Harvey H, Seaman J, Knight R, Costa L, Lipton A. Safety and efficacy of bisphosphonates beyond 24 months in cancer patients. *J Clin Oncol*. 2001;19(14):3434-7
- [67] Sutherland KA¹, Rogers HL, Tosh D, Rogers MJ. RANKL increases the level of Mcl-1 in osteoclasts and reduces bisphosphonate-induced osteoclast apoptosis in vitro. *Arthritis Res Ther*. 2009;11(2):R58.
- [68] Malan J¹, Ettinger K, Naumann E, Beirne O²The relationship of denosumab pharmacology and osteonecrosis of the jaws. *Oral Surg Oral Med Oral Pathol Oral Radiol*. 2012;114(6):671-6.
- [69] Estilo CL, Van Poznak CH, Williams T, Bohle GC, Lwin PT, Zhou Q, Riedel ER, Carlson DL, Schoder H, Farooki A, Fornier M, Halpern JL, Tunick SJ, Huryn JM. Osteonecrosis of the maxilla and mandible in patients with advanced cancer treated with bisphosphonate therapy. *Oncologist*. 2008;13(8):911-20.

- [70] Hansen T, Kunkel M, Weber A, James Kirkpatrick C. Osteonecrosis of the jaws in patients treated with bisphosphonates - histomorphologic analysis in comparison with infected osteoradionecrosis. *J Oral Pathol Med.* 2006;35:155-60.
- [71] Lugassy G, Shaham R, Nemets A, Ben-Dor D, Nahlieli O. Severe osteomyelitis of the jaw in long-term survivors of multiple myeloma: a new clinical entity. *Am J Med.* 2004;117(6):440-1.
- [72] Melo MD, Obeid G. Osteonecrosis of the jaws in patients with a history of receiving bisphosphonate therapy: strategies for prevention and early recognition. *J Am Dent Assoc.* 2005;136(12):1675-81.
- [73] Estilo CL, Van Poznak CH, Williams T, Bohle GC, Lwin PT, Zhou Q, Riedel ER, Carlson DL, Schoder H, Farooki A, Fornier M, Halpern JL, Tunick SJ, Huryn JM. Osteonecrosis of the maxilla and mandible in patients with advanced cancer treated with bisphosphonate therapy. 2008;13(8):911-20.
- [74] Jenkinson HF, Lamont RJ. Oral microbial communities in sickness and in health. *Trends Microbiol.* 2005;13(12):589-95.
- [75] Hall-Stoodley L, Stoodley P. Evolving concepts in biofilm infections. *Cell Microbiol.* 2009;11(7):1034-43.
- [76] Donlan RM, Costerton JW. Biofilms: survival mechanisms of clinically relevant microorganisms. *Clin Microbiol Rev.* 2002;15(2):167-93.
- [77] Chandra JI, Patel JD, Li J, Zhou G, Mukherjee PK, McCormick TS, Anderson JM, Ghannoum MA. Modification of surface properties of biomaterials influences the ability of *Candida albicans* to form biofilms. *Appl Environ Microbiol.* 2005;71(12):8795-801.
- [78] Badel T1, Pavicin IS, Carek AJ, Rosin-Grget K, Grbesa D Coll. Pathophysiology of osteonecrosis of the jaw in patients treated with bisphosphonate. *Antropol.* 2013;37(2):645-51.

- [79] Sedghizadeh PP, Kumar SK, Gorur A, Schaudinn C, Shuler CF, Costerton JW. Identification of microbial biofilms in osteonecrosis of the jaws secondary to bisphosphonate therapy. *J Oral Maxillofac Surg.* 2008;66(4):767-75.
- [80] Naik NH1, Russo TA. Bisphosphonate-related osteonecrosis of the jaw: the role of actinomyces. *Clin Infect Dis.* 2009;49(11):1729-32.
- [81] ABM Moniruddin, Hamida Begum, Khairun Nahar, Tanveer Ahmed, Maliha Alam Simi, M Mahbubur Rahman, M Kamruzzaman, Mohammad Sadiqul Amin. Actinomycosis: A Rare Disease. *J Medicine* 2010; 11: 74-77.
- [82] Neville BW, Damm DD, Allen CM, Bouquot JE. *Oral and maxillofacial pathology.* 2nd Ed. Philadelphia: Elsevier; 2002.
- [83] Könönen E, Wade WG. Actinomyces and related organisms in human infections. *Clin Microbiol Rev.* 2015;28(2):419-42.
- [84] Smego RA Jr, Foglia G. Actinomycosis. *Clin Infect Dis.* 1998;26(6):1255-61.
- [85] Wong VK, Turmezei TD, Weston VC. Actinomycosis. *BMJ.* 2011;343:d6099.
- [86] Funke G, Englert R, Frodl R, Bernard KA, Stenger S. *Actinomyces hominis* sp. nov., isolated from a wound swab. *Int J Syst Evol Microbiol.* 2010;60(Pt 7):1678-81.
- [87] Brailsford SR, Tregaskis RB, Leftwich HS, Beighton D. The predominant *Actinomyces* spp. isolated from infected dentin of active root caries lesions. *J Dent Res.* 1999;78(9):1525-34.
- [88] Kumar SK, Gorur A, Schaudinn C, Shuler CF, Costerton JW, Sedghizadeh PP. The role of microbial biofilms in osteonecrosis of the jaw associated with bisphosphonate therapy. *Curr Osteoporos Rep.* 2010;8(1):40-8.
- [89] Abu-Id MH, Warnke PH, Gottschalk J, Springer I, Wiltfang J, Acil Y, Russo PA, Kreusch T. "Bis-phossoy jaws" - high and low risk factors for bisphosphonate-induced osteonecrosis of the jaw. *J Craniomaxillofac Surg.* 2008;36(2):95-103.

- [90] Biasotto M, Chiandussi S, Dore F, Rinaldi A, Rizzardi C, Cavalli F, Di Lenarda R. Clinical aspects and management of bisphosphonates-associated osteonecrosis of the jaws. *Acta Odontol Scand.* 2006;64(6):348-54.
- [91] Bisdas S1, Chambron Pinho N, Smolarz A, Sader R, Vogl TJ, Mack MG. Biphosphonate-induced osteonecrosis of the jaws: CT and MRI spectrum of findings in 32 patients. *Clin Radiol.* 2008;63(1):71-7.
- [92] Hansen T, Kunkel M, Springer E, Walter C, Weber A, Siegel E, et al. Actinomycosis of the jaws--histopathological study of 45 patients shows significant involvement in bisphosphonate-associated osteonecrosis and infected osteoradionecrosis. *Virchows Arch.* 2007;451(6):1009-17.
- [93] Kaya D, Demirezen S, Hascelik G, Gulmez Kivanc D, Beksac MS. Comparison of PCR, culturing and Pap smear microscopy for accurate diagnosis of genital Actinomyces. *J Med Microbiol.* 2013;62:727-33.
- [94] Wade WG. Has the use of molecular methods for the characterization of the human oral microbiome changed our understanding of the role of bacteria in the pathogenesis of periodontal disease? *J Clin Periodontol.* 2011;38 Suppl 11:7-16.
- [95] Kolbert CP, Persing DH. Ribosomal DNA sequencing as a tool for identification of bacterial pathogens. *Curr Opin Microbiol.* 1999;2(3):299-305.
- [96] Favia G, Pilolli GP, Maiorano E. Osteonecrosis of the jaw correlated to bisphosphonate therapy in non-oncologic patients: clinicopathological features of 24 patients. *J Rheumatol.* 2009;36(12):2780-7.
- [97] Otto S, Pautke C, Hafner S, Hesse R, Reichardt LF, Mast G, Ehrenfeld M, Cornelius CP. Pathologic fractures in bisphosphonate-related osteonecrosis of the jaw-review of the literature and review of our own cases. *Craniofac Trauma Reconstr.* 2013;6(3):147-54.

- [98] Katsarelis H, Shah NP, Dhariwal DK, Pazianas M. Infection and medication-related osteonecrosis of the jaw. *J Dent Res*. 2015;94(4):534-9.
- [99] Boff RC, Salum FG, Figueiredo MA, Cherubini K. Important aspects regarding the role of microorganisms in bisphosphonate-related osteonecrosis of the jaws. *Arch Oral Biol*. 2014 Aug;59(8):790-9.
- [100] Lau SK, Woo PC, Fung AM, Chan KM, Woo GK, Yuen KY. Anaerobic, non-sporulating, Gram-positive bacilli bacteraemia characterized by 16S rRNA gene sequencing. *J Med Microbiol*. 2004;53(Pt 12):1247-53.
- [101] Elsayed S, Plewes K, Church D, Chow B, Zhang K. Use of molecular beacon probes for real-time PCR detection of *Plasmodium falciparum* and other plasmodium species in peripheral blood specimens. *J Clin Microbiol*. 2006;44(2):622-4.
- [102] Kim KM, Rhee Y, Kwon YD, Kwon TG, Lee JK, Kim DY. Medication Related Osteonecrosis of the Jaw: 2015 Position Statement of the Korean Society for Bone and Mineral Research and the Korean Association of Oral and Maxillofacial Surgeons. *J Bone Metab*. 2015;22(4):151-65.
- [103] Aspenberg P, Schilcher J, Fahlgren A. Histology of an undisplaced femoral fatigue fracture in association with bisphosphonate treatment. Frozen bone with remodelling at the crack. *Acta Orthop*. 2010;81(4):460-2.
- [104] Sedghizadeh PP, Kumar SK, Gorur A, Schaudinn C, Shuler CF, Costerton JW. Microbial biofilms in osteomyelitis of the jaw and osteonecrosis of the jaw secondary to bisphosphonate therapy. *J Am Dent Assoc*. 2009;140(10):1259-65.
- [105] Lopes RN, Rabelo GD, Rocha AC, Carvalho PA, Alves FA. Surgical Therapy for Bisphosphonate-Related Osteonecrosis of the Jaw: Six-Year Experience of a Single Institution. *J Oral Maxillofac Surg*. 2015;73(7):1288-95.
- [106] Vahtsevanos K, Kyrgidis A, Verrou E, Katodritou E, Triaridis S, Andreadis CG, Boukovinas I, Koloutsos GE, Teleioudis Z, Kitikidou K, Paraskevopoulos P, Zervas K, Antoniadis K.

Longitudinal cohort study of risk factors in cancer patients of bisphosphonate-related osteonecrosis of the jaw. *J Clin Oncol*. 2009;27(32):5356-62.

- [107] Neviasser AS, Lane JM, Lenart BA, Edobor-Osula F, Lorich DG. Low-energy femoral shaft fractures associated with alendronate use. *J Orthop Trauma*. 2008;22(5):346-50.
- [108] Fliefel R, Tröltzsch M, Kühnisch J, Ehrenfeld M, Otto S. Treatment strategies and outcomes of bisphosphonate-related osteonecrosis of the jaw (BRONJ) with characterization of patients: a systematic review. *Int J Oral Maxillofac Surg*. 2015;44(5):568-85.
- [109] O'Ryan FS, Lo JC. Bisphosphonate-related osteonecrosis of the jaw in patients with oral bisphosphonate exposure: clinical course and outcomes. *J Oral Maxillofac Surg*. 2012;70(8):1844-53.
- [110] Hoff AO, Toth BB, Altundag K, Johnson MM, Warneke CL, Hu M, Nooka A, Sayegh G, Guarneri V, Desrouleaux K, Cui J, Adamus A, Gagel RF, Hortobagyi GN. Frequency and risk factors associated with osteonecrosis of the jaw in cancer patients treated with intravenous bisphosphonates. *J Bone Miner Res*. 2008;23(6):826-36.
- [111] Mozzati M, Arata V, Gallesio G. Tooth extraction in osteoporotic patients taking oral bisphosphonates. *Osteoporos Int*. 2013;24(5):1707-12.
- [112] Khosla S, Burr D, Cauley J, Dempster DW, Ebeling PR, Felsenberg D, Gagel RF, Gilsanz V, Guise T, Koka S, McCauley LK, McGowan J, McKee MD, Mohla S, Pendrys DG, Raisz LG, Ruggiero SL, Shafer DM, Shum L, Silverman SL, Van Poznak CH, Watts N, Woo SB, Shane E; American Society for Bone and Mineral Research. Bisphosphonate-associated osteonecrosis of the jaw: report of a task force of the American Society for Bone and Mineral Research. *J Bone Miner Res*. 2007;22(10):1479-91.
- [113] O'Ryan FS, Khoury S, Liao W, Han MM, Hui RL, Baer D, Martin D, Liberty D, Lo JC. Intravenous bisphosphonate-related osteonecrosis of the jaw: bone scintigraphy as an early indicator. *J Oral Maxillofac Surg*. 2009;67(7):1363-72.

- [114] Otto S, Pautke C, Hafner S, Hesse R, Reichardt LF, Mast G, Ehrenfeld M, Cornelius CP. Pathologic fractures in bisphosphonate-related osteonecrosis of the jaw-review of the literature and review of our own cases. *Craniomaxillofac Trauma Reconstr.* 2013;6(3):147-54.
- [115] Drancourt M, Bollet C, Carlioz A, Martelin R, Gayral JP, Raoult D. 16S ribosomal DNA sequence analysis of a large collection of environmental and clinical unidentifiable bacterial isolates. *J Clin Microbiol.* 2000;38(10):3623-30.
- [116] Otto S. *Medication-Related Osteonecrosis of the Jaws.* Berlin Heidelberg: Springer; 2015.
- [117] Dimopoulos MA, Kastritis E, Anagnostopoulos A, Melakopoulos I, Gika D, Moulopoulos LA, Bamia C, Terpos E, Tsionos K, Bamias A. Osteonecrosis of the jaw in patients with multiple myeloma treated with bisphosphonates: evidence of increased risk after treatment with zoledronic acid. *Haematologica.* 2006;968-71.
- [118] Dimopoulos MA, Kastritis E, Bamia C, Melakopoulos I, Gika D, Roussou M, Migkou M, Eleftherakis-Papaiakovou E, Christoulas D, Terpos E, Bamias A. Reduction of osteonecrosis of the jaw (ONJ) after implementation of preventive measures in patients with multiple myeloma treated with zoledronic acid. *Ann Oncol.* 2009;20(1):117-20.
- [119] Vandone AM, Donadio M, Mozzati M, Ardine M, Polimeni MA, Beatrice S, Ciuffreda L, Scoletta M. Impact of dental care in the prevention of bisphosphonate-associated osteonecrosis of the jaw: a single-center clinical experience. *Ann Oncol.* 2012;23(1):193-200.
- [120] Sivoilella S, Lumachi F, Stellini E, Favero L. Denosumab and anti-angiogenic drug-related osteonecrosis of the jaw: an uncommon but potentially severe disease. *Anticancer Res.* 2013;33(5):1793-7.
- [121] Smidt-Hansen T, Folkmar TB, Fode K, Agerbaek M, Donskov F. Combination of zoledronic Acid and targeted therapy is active but may induce osteonecrosis of the jaw in patients with metastatic renal cell carcinoma. *J Oral Maxillofac Surg.* 2013;71(9):1532-40.

- [122] Fehm T, Felsenberg D, Krimmel M, Solomayer E, Wallwiener D, Hadjii P. Bisphosphonate-associated osteonecrosis of the jaw in breast cancer patients: recommendations for prevention and treatment. *Breast*. 2009;18(4):213-7.
- [123] Fehm T, Beck V, Banys M, Lipp HP, Hairass M, Reinert S, Solomayer EF, Wallwiener D, Krimmel M. Bisphosphonate-induced osteonecrosis of the jaw (ONJ): Incidence and risk factors in patients with breast cancer and gynecological malignancies. *Gynecol Oncol*. 2009;112(3):605-9.
- [124] Hellstein JW¹, Adler RA, Edwards B, Jacobsen PL, Kalmar JR, Koka S, Migliorati CA, Ristic H; American Dental Association Council on Scientific Affairs Expert Panel on Antiresorptive Agents. Managing the care of patients receiving antiresorptive therapy for prevention and treatment of osteoporosis: executive summary of recommendations from the American Dental Association Council on Scientific Affairs. *J Am Dent Assoc*. 2011;142(11):1243-51.

8 ACKNOWLEDGEMENTS

I would like to express my deep appreciation and gratitude to my advisor, PD. Dr. Sven Otto, for the patient guidance and mentorship he provided to me, all the way from when I was first considering applying to the Dr. med program. Dr. Otto's intellectual heft is matched only by his genuinely good nature and down-to earth humility, and one simply could not wish for a better or friendlier supervisor.

I would like to thank Riham Fliefel and Madlen Runge, my fellow doctoral students, and my lovely friend Andrew Boyer for their feedback, cooperation, support in overcoming numerous obstacle and of course friendship

The Department of Oral and Maxillofacial Surgery Ludwig-Maximilians-University of Munich Director: Prof. Dr. Dr. Michael Ehrenfeld has provided the support and equipment I have needed to produce and complete my thesis and Chulalongkorn University who has funded my studies.

Last but not least, I would like to thank my family; my parents and to my sister and brother for supporting me spiritually throughout writing this thesis and my life in general.

9 APPENDIX

Appendix 1: Common Antiresorptive agents [124]

Antiresorptive agents					
Brand Name	Generic Name	Dosage	Manufacture	Approved (Date)	Indications
Oral Formulations					
Actonel	Risedronate sodium	5-, 35-, 75- and 150-milligram tablets	Warner Chilcott, Dublin	Worldwide (1998)	To prevent and treat osteoporosis in post-menopausal women To prevent and treat osteoporosis in men and women caused by steroid treatment To treat Paget disease of bone in men and women
Atelvia	Risedronate sodium	35-mg tablet (once/weekly)	Warner Chilcott	Worldwide (2010)	To treat osteoporosis in post-menopausal women
Bonefos	Clodronate disodium	400-mg capsules (Canada), 800-mg tablets (Europe)	Bayer, Toronto	Canada (1992)	To prevent and treat osteoporosis in post-menopausal women
			Bayer, Berlin	Europe (1985)	To treat hypercalcemia and osteolysis due to malignancy To reduce occurrence of bone metastasis in primary breast cancer
Boniva	Ibandronate sodium	2.5-mg tablet once daily, 150-mg	Genentech, South San Francisco, Calif.	United States (2003)	To prevent and treat osteoporosis in post-menopausal women
Bonviva	Ibandronate sodium	150-mg tablet once monthly	Genentech	Europe (2004)	To prevent and treat osteoporosis in post-menopausal women
Didronel	Etidronate sodium	400-mg tablets	Warner Chilcott	United States (1983), Europe	To treat Paget disease of bone To prevent and treat heterotopic ossification in people who have undergone total hip replacement or in people who have and injury to the spinal cord
Etidronate	Etidronate	200-, 400-mg tablets	Mylan Pharmaceuticals, Morgantown, W.V.	United States (2003),	Note: off-label use to prevent and treat osteoporosis caused by steroid treatment

Fosamax	Alendronate sodium	5-, 10-, 35-, 40- and 70-mg tablets	Merck & Co., Whitehouse Station, N.J.	United States (1995)	To prevent and treat osteoporosis in post-menopausal women and increase bone mass in men with osteoporosis
				Europe (1995)	To treat Paget disease of bone To prevent and treat osteoporosis in men and women caused by steroid treatment
Fosamax Plus D	Alendronate sodium/ cholecalciferol	70-mg tablet or 70-mg oral solution	Merck & Co.	United States (2005), Europe (2005)	To prevent and treat osteoporosis in post-menopausal women and increase bone mass in men with osteoporosis
Generic alendronate	Alendronate sodium	5-, 10-, 35-, 40- and 70-mg tablets	Various	Worldwide (2008)	To prevent and treat osteoporosis in post-menopausal women and increase bone mass in men with osteoporosis To treat Paget disease of bone To prevent and treat osteoporosis in men and women caused by steroid treatment
Skelid	Tiludronate disodium	240-mg tablets (equivalent to 200-mg base)	Sanofi-Aventis, Bridgewater, N.J.	United States (1997)	To treat Paget disease of bone
Aredia	Pamidronate disodium	30-, 90-mg vials	Novartis Pharmaceuticals, East Hanover, N.J.	Worldwide (2001)	To treat moderate or severe hypercalcemia with malignancy, with or without bone metastases To treat osteolytic bone metastasis of breast cancer and osteolytic lesion of multiple myeloma in conjunction with standard antineoplastic therapy To treat Paget disease of bone

Antiresorptive agents					
Brand Name	Generic Name	Dosage	Manufacture	Approved (Date)	Indications
Parenteral Formulation					
Bonefos	Clodronate disodium	60-mg/ 1 millilitre, 1,500-mg single dose	Bayer, Toronto	Canada (1992)	To treat Paget disease of bone
			Bayer, Schering	Europe (1985)	To treat hypercalcemia due to metastatic bone disease, multiple myeloma and parathyroid carcinoma
Boniva IV	Ibandronate sodium	3mg/3 ml single use	Genetech	United States (2006), Europe (2006)	To treat osteoporosis in postmenopausal women
Prolia	Denosumab	60-mg subcutaneous injection every six month	Amgen, Thousand Oaks, Calif.	United States (2010), Europe (2010)	To prevent skeletally related events in patients with bone metastases from solid tumors
XGEVA	Denosumab	120-mg in 1.7-mL subcutaneous injection every four weeks	Amgen	United States -2010	To prevent skeletally related events in patients with bone metastases from solid tumors
Reclast (US.)	Zoledronic acid	5-mg in a 100-mL ready-to-infuse solution	Novartis Phamaceuticals	United States (Reclast) (2007)	To prevent and treat osteoporosis in post-menopausal women and increase bone mass in men with osteoporosis
Aclasta (Europe)				Worldwide (Aclasta) (2005)	To prevent and treat glucocorticoid-induced osteoporosis in patients expected to receive glucocorticoid therapy for at least 12 months
Zometa	Zoledronic acid	4-mg/5-mL single-dose vials	Novartis Phamaceuticals	Worldwide (2001)	To reduce delay bone complication due to multiple myeloma and bone metastases from solid tumors, in conjunction with anticancer medications

Appendix 2: Patient history parameter List

Age (years)

Gender: Male / Female

Primary cause of antiresorptive agents

- Breast cancer
- Prostate cancer
- Multiple myeloma
- Osteoporosis
- Lung cancer
- Other (Colon, Systemic, Mastocytosis, Renal, Bladder, Thyroid, Endometrium)

Comorbidities

- Diabetes Mellitus
- Cardiovascular disease
- Chemotherapy
- Irradiation
- Steroid intake
- Antiangiogenetic drugs
- Smoking

Type of Antiresorptive drug (ARD)

Bisphosphonate:

- Zoledronate
- Pamidronate
- Ibandronate
- Combination
- Denosumab
-

Route of administration

- Intravenous
- Oral
- Subcutaneous

Staging of MRONJ: stage 0-3

Clinical presentation

- Pain
- Exposed bone
- Inflammation
- Disturbance in wound healing
- Swelling
- Pus presentation

- Fistula
- Pathological fracture (Mandible)
- Sinus involvement (Maxilla)

Location: tooth area

- Mandible
- Maxilla
- Both

Triggering events

- Extractions
- Other Dentoalveolar surgery
- Denture sore
- Periodontal lesion&treatment
- Spontaneous

Prevention

- Dentist visited before antiresorptive medication
- Stop antiresorptive after ONJ diagnosis

Appendix 3: List of finding bacteria

Species list			
1	<i>Actinomyces species</i>	36	<i>Klebsiella pneumoniae</i>
2	<i>Actinomyces odontolyticus</i>	37	<i>Klebsiella oxytoca</i>
3	<i>Actinomyces naeslundii</i>	38	<i>Koagulase neg. Staphylokokken</i>
4	<i>Aggregatibacter aphrophilus</i>	39	<i>Lactobacillus species</i>
5	<i>Atopobium species</i>	40	<i>Morganella morganii</i>
6	<i>Anaerobe mischflora</i>	41	<i>Mundflora</i>
7	<i>Anaerobe mundflora</i>	42	<i>Neisseria species</i>
8	<i>Bacteroides thetaiofaomicron</i>	43	<i>Neisseria mucosa</i>
9	<i>Bacteroides fragillis</i>	44	<i>Olsenella uli</i>
10	<i>Bacteroides uniformis</i>	45	<i>Parvimonas micra</i>
11	<i>Bacteroides stercoris</i>	46	<i>Parabacteroides distasonis</i>
12	<i>Biophila wadsworthia</i>	47	<i>Peptostreptococcus species</i>
13	<i>Clostridium species</i>	48	<i>Prevotella species</i>
14	<i>Candida species</i>	49	<i>Prevotella intermedia</i>
15	<i>Candida albicans</i>	50	<i>Prevotella buccae</i>
16	<i>Candida krusei</i>	51	<i>Prevotella melaninogenica</i>
17	<i>Candida grabrata</i>	52	<i>Prevotella nigrescens</i>
18	<i>Candida tropicalis</i>	53	<i>Porphyromonas species</i>
19	<i>Campyrobacter rectus</i>	54	<i>Porphyromonas asaccharolyticus</i>
20	<i>Citrobacter freundii</i>	55	<i>Porphyromonas gingivalis</i>
21	<i>Corynebacterium species</i>	56	<i>Propionibacterium propionicum</i>
22	<i>Eikenella corrodens</i>	57	<i>Propionibacterium acnes</i>
23	<i>Enterobacter aerogenes</i>	58	<i>Providencia vettgeri</i>
24	<i>Enterobacter cloacae</i>	59	<i>Proteus vulgaris</i>
25	<i>Enterobacter cloacae complex</i>	60	<i>Serratia marcescens</i>
26	<i>Enterococcus avium</i>	61	<i>Serratia ureilytica</i>
27	<i>Enterococcus faecalis</i>	62	<i>Streptococcus anginosus</i>
28	<i>Escherichia coli</i>	63	<i>Streptococcus parasanguinius</i>
29	<i>Fusobacterium mortiferum</i>	64	<i>Streptococcus gordonii</i>
30	<i>Fusobacterium necrophorum</i>	65	<i>Streptococcus cohnii</i>
31	<i>Fusobacterium nucleatum</i>	66	<i>Vergruenende streptokokken</i>
32	<i>Haemophilus parainfluenzae</i>	67	<i>Veillonella species</i>
33	<i>Haemophilus influenza</i>	68	<i>Veillonella parvula</i>
34	<i>Hafnia alvei</i>	69	<i>Veillonella denticariosi</i>
35	<i>Haemolysierende Streptococcus gr.F</i>		

Appendix 4: Publication list

Panya S, Fliefel R, Probst F, Tröltzsch M, Ehrenfeld M, Schubert S, Otto S,

Role of microbiological culture and polymerase chain reaction (PCR) of Actinomyces in Medicationrelated Osteonecrosis of the jaw (MRONJ), Journal of Cranio-Maxillofacial Surgery (2017), doi: 10.1016/j.jcms.2017.01.006.

