

Aus der urologischen Klinik und Poliklinik
der Ludwig-Maximilians-Universität München

Direktor: Prof. Dr. med. Christian Stief

Imaging in Renal Cell Carcinoma
A Systematic Review

Dissertation
zum Erwerb des Doktorgrades der Medizin
an der Medizinischen Fakultät der
Ludwig-Maximilians-Universität zu München

vorgelegt von
Christina Vogel
aus Hannover
2017

Mit Genehmigung der Medizinischen Fakultät
der Universität München

Berichterstatter:	Prof. Dr. med. Michael Staehler
Mitberichterstatter:	Prof. Dr. med. Christian Chaussy Priv. Doz. Dr. med. Heike Pohla Prof. Dr. med. Dr. h.c. Dirk-André Clevert
Dekan:	Prof. Dr. med. dent. Reinhard Hickel
Tag der mündlichen Prüfung:	05.10.2017

Contents

List of abbreviations	5
1. Introduction	6
1.1 Renal cell carcinoma	6
1.1.1 TNM classification [6]	7
1.1.2 TNM classification [6]	7
1.1.3 Stage grouping	7
1.2 Imaging in renal masses	8
1.3 Aims of the review	8
2. Methods	9
2.1 Principles of systematic reviews	9
2.2 Search strategy	10
2.2.1 Search strategy for Medline, Medline In-Process and Embase	10
2.3 Study selection	12
2.4 Data abstraction and risk of bias assessment	13
2.5 Outcome measures and synthesis	15
3. Findings	16
3.1 Study selection	16
3.2 Imaging	17
3.2.1 Contrast-enhanced CT	23
3.2.2 MRI	25
3.2.3 Ultrasound	27
3.2.3.1 Unenhanced sonography	27
3.2.3.2 Colour Doppler ultrasound	28
3.2.3.3 Contrast-enhanced ultrasound (CEUS)	28
3.2.4 PET/CT	29
3.3 Subgroup analysis	30
3.3.1 Small renal masses	30
3.3.2 Complex cystic renal masses	31
3.3.3 Differentiation of renal cell carcinoma from angiomyolipoma	31
3.4 Staging of RCC	32
3.5 Risk of bias	33
4. Discussion	34
4.1 Summary of evidence	34
4.2 Strengths and limitations of the review	35
4.3 Factors influencing diagnostic confidence	36
4.4 Contraindications and side effects	37
5. Conclusions	38
Summary	39
Zusammenfassung	40

Bibliography	42
Danksagung	45

List of abbreviations

ADC	apparent diffusion coefficient
AML	angiomyolipoma
BOLD	blood oxygen level-dependent
ccRCC	clear cell renal cell carcinoma
CECT	contrast-enhanced computed tomography
CE MRI	contrast-enhanced magnetic resonance imaging
CEUS	contrast-enhanced ultrasound
chRCC	chromophobe renal cell carcinoma
DCE	dynamic contrast-enhanced
DTA	diagnostic test accuracy
DW	diffusion-weighted
EAU	European Association of Urology
FDG	fludeoxyglucose
IQR	interquartile range
MRI	magnetic resonance imaging
NPV	negative predictive value
PDUS	power Doppler ultrasound
PET/CT	positron emission tomography-computed tomography
PICO	population, intervention, comparison and outcomes
PPV	positive predictive value
pRCC	papillary renal cell carcinoma
PRISMA	Preferred Reporting Items for Systematic Reviews and Meta-Analyses
QUADAS	Quality Assessment of Diagnostic Accuracy Studies
RCC	renal cell carcinoma
SRM	small renal masses (≤ 4 cm)

1. Introduction

1.1 Renal cell carcinoma

The incidence of renal cell carcinoma (RCC) is still rising in most countries of the world. At the same time stabilisation or even decrease of mortality has been accomplished in many countries of Europe and North America [1]. On the one hand, these trends can be explained by the increase of incidentally detected renal masses with better prognosis owing to the widespread use of ultrasound and CT [2, 3]. On the other hand, the availability of improved therapeutic measures in highly developed countries has led to declining mortality trends [1].

With an estimated 338,000 new cases of kidney cancer in 2012 it constitutes 2-3% of all cancer cases worldwide [4]. Rates vary strongly, with the highest incidence in Western countries [1].

RCC represents more than 90% of these malignant renal tumours [5]. The three main histologic types are clear cell, papillary and chromophobe RCC [6]. Risk factors include tobacco smoking, obesity, hypertension and a positive family history for renal cancer [7]. A protective effect has been reported for a diet rich in fruit and vegetables [7] as well as for moderate alcohol consumption [8]. There are a number of genetic cancer syndromes associated with RCC, such as Von-Hippel-Lindau disease, hereditary papillary renal cell carcinoma, hereditary leiomyomatosis and renal cell cancer and Birt-Hogg-Dubé syndrome [5].

Clinically, the classic triad of gross haematuria, flank pain and abdominal mass has become rare [3]. Other possible clinical manifestations include systemic symptoms such as anorexia, fever, abdominal pain or paraneoplastic syndromes [5]. However, if RCC becomes symptomatic, it has often reached a more advanced stage with a poorer prognosis [9]. Haematogenous metastatic spread is common and in some cases already present at an early stage of disease [5]. Apart from tumour stage, important prognostic factors include Fuhrman grade, RCC subtype, sarcomatoid features, clinical and molecular factors [10]. The five-year overall survival rate for all types of RCC is currently 49% [11].

1.1.2 TNM classification [6]

TX	Primary tumour cannot be assessed
T0	No evidence of primary tumour
T1	Tumour 7 cm or less in greatest dimension, limited to the kidney
T1a	Tumour 4 cm or less
T1b	Tumour more than 4 cm but not more than 7 cm
T2	Tumour more than 7 cm in greatest dimension, limited to the kidney
T3	Tumour extends into major veins or directly invades adrenal gland or perinephric tissues but not beyond Gerota fascia
T3a	Tumour directly invades adrenal gland or perinephric tissues but not beyond Gerota fascia
T3b	Tumour grossly extends into renal vein(s) or vena cava or its wall below diaphragm
T3c	Tumour grossly extends into vena cava or its wall above diaphragm
T4	Tumour directly invades beyond Gerota fascia
NX	Regional lymph nodes cannot be assessed
N0	No regional lymph node metastasis
N1	Metastasis in a single regional lymph node
N2	Metastasis in more than one regional lymph node
MX	Distant metastasis cannot be assessed
M0	No distant metastasis
M1	Distant metastasis

1.1.3 Stage grouping

Stage I	T1	N0	M0
Stage II	T2	N0	M0
Stage III	T3	N0	M0
	T1, T2, T3	N1	M0
Stage IV	T4	N0, N1	M0
	any T	N2	M0
	any T	any N	M1

1.2 Imaging in renal masses

For treatment planning an accurate diagnosis is essential. The majority of renal tumours is found incidentally when imaging is done for other medical reasons [3]. The most commonly used imaging techniques to then assess these incidental renal masses are ultrasound, CT and MRI [10]. In most cases an accurate characterisation of renal tumours is possible just by imaging [10]. Nevertheless, there are a number of factors that can hamper a reliable diagnosis. With the growing number of incidentally detected RCC, also the amount of unexpected benign renal masses at resection has increased [12]. Not only technical factors, but also errors in image interpretation as well as certain pathologic features can lead to misdiagnosis and in some cases even unnecessary surgery [13].

1.3 Aims of the review

The aim of this review is to assess the diagnostic performance of conventional contrast-enhanced CT in comparison to other imaging modalities for diagnosing and staging RCC in adults. To this end, we systematically searched electronic databases for studies examining different imaging modalities in the characterisation of renal masses and then evaluated the eligible studies.

To our knowledge, no systematic review on this subject has been done so far although there is a great need for an overview and an evaluation of the numerous studies that have looked into the imaging of renal masses.

2. Methods

2.1 Principles of systematic reviews

Systematic reviews and meta-analyses have become essential in evidence-based medicine. Their purpose is not only to give a comprehensive and structured overview of the current research findings in a certain field. In many cases they are also used as a starting point for clinical guidelines or as an identification of gaps in knowledge and the need for further research [14]. In contrast to traditional reviews, systematic reviews and meta-analyses are objective, rigorous, transparent and reproducible.

For conducting a systematic review, a precise research question and a search strategy need to be defined in the beginning. Then, a literature search is conducted through different electronic databases. The abstracts emerging from the literature search are screened according to a pre-specified study screening form. Afterwards, the selected studies are retrieved as full-text papers and screened again, applying inclusion and exclusion criteria. Relevant data is extracted from the included full-texts into a data abstraction table and methodological quality is assessed. If a meta-analysis is possible, the results from two or more studies are combined using specific statistical techniques [15]. Finally, the data is evaluated and presented within the framework of a systematic review or, if possible, a meta-analysis.

The review we performed was a systematic review on diagnostic test accuracy (DTA), which differs from the more common reviews or meta-analyses on interventions or therapies. The statistical part of these reviews tends to be more challenging, as there is usually a pair of outcomes (such as sensitivity and specificity) that needs to be analysed, instead of a single outcome [15]. Heterogeneity of results is very common, making meta-analysis impossible in many cases [15]. However, for DTA reviews, it is possible to address different questions and comparisons in the same article [15]. The instrument recommended by the Cochrane collaboration for assessing methodological quality in DTA reviews is the QUADAS-2 tool [16].

There are a number of different guidelines and manuals for the realisation of systematic reviews and meta-analyses. Our systematic review was implemented in

accordance with the Preferred Reporting Items for Systematic Reviews and Meta-Analyses (PRISMA) [14] and the Cochrane Handbook for Diagnostic Test Accuracy Reviews.

2.2 Search strategy

A comprehensive literature search was conducted through the electronic databases Medline, Medline In-Process, Embase, The Cochrane Library, Latin American and Caribbean Health Sciences (LILACS), Web of Science as well as through conference proceedings (2012 and 2013 ASCO Annual Meeting). The search strategy for Medline, Medline In-Process and Embase can be seen below. Search items comprised “renal cell carcinoma” and related terms as the target condition, imaging modalities and outcomes specified in our study screening form and appropriate types of studies. The search was limited to articles published from 1st January 2000 to 31st March 2016. No language restrictions were applied.

2.2.1 Search strategy for Medline, Medline In-Process and Embase

1. Carcinoma, Renal Cell/ use prmz
2. kidney carcinoma/ use oomezd
3. ((kidney or renal) adj2 (cancer* or carcinoma* or neoplasm* or tum?or* or mass*)).tw.
4. or/1-3
5. *multidetector computed tomography/ use prmz
6. *nuclear magnetic resonance imaging/ or diffusion tensor imaging/ or echo planar imaging/ or functional magnetic resonance imaging/ or interventional magnetic resonance imaging/
7. echography/ use oomezd
8. exp *computer assisted tomography/ use oomezd
9. exp *tomography, emission-computed/ use prmz
10. *urography/ use prmz
11. *intravenous urography/ use oomezd
12. *magnetic resonance imaging/

13. (MDCT or CECT or CT-PET or magnetic resonance imaging or MRI or ultrasound or ultrasonography or computed tomography or CT-positron emission tomography or urography).tw.
14. or/5-13
15. "sensitivity and specificity"/
16. roc curve/
17. receiver operating characteristic/ use oomezd
18. predictive value of tests/
19. diagnostic errors/ use oomezd
20. false positive reactions/ use prmz
21. false negative reactions/ use prmz
22. diagnostic accuracy/ use oomezd
23. diagnostic value/ use oomezd
24. du.fs. use prmz
25. sensitivity.tw.
26. distinguish\$.tw.
27. differentiat\$.tw.
28. identif\$.tw.
29. detect\$.tw.
30. diagnos\$.tw.
31. (predictive adj4 value\$.tw.
32. accura\$.tw.
33. or/15-32
34. comparative study/ use prmz
35. follow-up studies/ use prmz
36. time factors/ use prmz
37. Treatment outcome/ use oomezd
38. major clinical study/ use oomezd
39. controlled study/ use oomezd
40. (preoperat\$ or pre operat\$).tw.
41. (prospective\$ or retrospective\$).tw.
42. (cohort\$ or case series).tw.
43. (compare\$ or compara\$).tw.
44. case report/ use oomezd
45. case reports.pt.
46. exp clinical trial/
47. randomized controlled trial.pt.
48. controlled clinical trial.pt.

49. randomization/ use oemezd
50. randomi?ed.ab.
51. randomly.ab.
52. trial.ab.
53. groups.ab.
54. or/34-53
55. 4 and 14 and 33 and 54
56. Carcinoma, Renal Cell/di [Diagnosis]
57. kidney carcinoma/di [Diagnosis]
58. 14 and (56 or 57)
59. 55 or 58
60. exp animals/ not humans/
61. (letter or editorial or comment* or review or note).pt.
62. 59 not (60 or 61)
63. limit 62 to yr="2000 -Current"

2.3 Study selection

All titles and abstracts matching the search items were screened by two independent reviewers. Screening was done according to a pre-specified study screening form. The selected abstracts were then retrieved as full texts and screened again independently by the two reviewers.

For inclusion, the following pre-defined inclusion criteria had to be fulfilled:

- The target condition had to be RCC
- The studies were required to report at least sensitivity and specificity data
- The reference standard had to be pathological confirmation for test-positives and either pathology or CT/MRI follow-up for test-negatives
- Possible comparator tests were:
 - (Dynamic) contrast-enhanced computed tomography (CECT)
 - Non-contrast CT
 - Multidetector CT
 - Ultrasonography
 - Contrast-enhanced ultrasound (CEUS)

- Doppler ultrasound
- Intravenous urography
- Plain MRI
- Contrast-enhanced MRI
- Diffusion-weighted MRI
- Positron emission tomography (PET)
- PET/CT

Furthermore, the following exclusion criteria were applied:

- Case reports with < 10 patients
- Studies with patients under 18 years of age
- Studies with < 1 year of follow-up

Other reasons for exclusion were irrelevant outcome data, the lack of data for the target condition, incomplete data, inadequate reference standard, reviews, comments and meta-analyses. Disagreement between the two reviewers was resolved by consensus or by consulting a third person.

2.4 Data abstraction and risk of bias assessment

Following full text screening, data from the selected studies was extracted into an appropriate data abstraction form. Information was collected about the study design, aims and conclusions of the study, patient and tumour characteristics, reference standard, interventions and outcome measures.

Subsequently, the risk of bias for each study was assessed using the QUADAS-2 tool [16]. This tool consists of four domains: patient selection, index test, reference standard and flow and timing. A summary of the risk of bias assessment can be found in figure 1.

	Risk of Bias				Applicability Concerns		
	Patient Selection	Index Test	Reference Standard	Flow and Timing	Patient Selection	Index Test	Reference Standard
Ak 2005	High	Unclear	Unclear	Low	Low	Low	Low
Chen 2015	Low	Low	Unclear	Low	Low	Low	Low
Choi 2012	Unclear	Unclear	Unclear	Low	Low	Low	Low
Divgi 2013	Unclear	Unclear	Low	Unclear	Low	Low	Low
Hallscheidt 2004	Low	Unclear	Unclear	Unclear	Low	Low	Low
Hallscheidt 2005	Low	Low	Unclear	Low	Low	Low	Low
Hedgire 2013	Low	Unclear	Unclear	Low	Low	Low	Low
Hindman 2012	Low	Low	Unclear	Unclear	Low	Low	Low
Ho 2012	Low	Unclear	Unclear	Low	Low	Low	Low
Ignee 2010	Low	Unclear	Unclear	Unclear	Low	Low	Low
Jiang 2008	High	Unclear	Unclear	Unclear	Low	Low	Low
Karlo 2013a	Low	Low	Unclear	Low	Low	Low	Low
Karlo 2013b	Low	Low	Unclear	Low	Low	Low	Low
Karlo 2013c	Low	Low	Unclear	Low	Low	Low	Low
Khan 2008	High	Unclear	Unclear	Unclear	Low	Low	Low
Kim 2002	Low	Unclear	Low	Unclear	Low	Low	Low
Kim 2009	Low	Low	Unclear	Unclear	Low	Low	Low
Kim 2012	Low	Unclear	Low	Low	Low	Low	Low
Kim 2016	Low	Low	Unclear	Low	Low	Low	Low
Kutman 2013	Low	Unclear	Unclear	Low	Low	Low	Low
Li 2011	Unclear	Low	Low	Low	Low	Low	Low
Li 2013	Unclear	Unclear	Unclear	Low	Low	Low	Low
Lu 2015b	Low	Unclear	Unclear	Unclear	Low	Low	Low
Notohamiprodjo 2013	Unclear	Unclear	Unclear	Low	Low	Low	Low
Pedrosa 2008	Low	Low	Low	Unclear	Low	Low	Low
Quaia 2008	Low	Low	Unclear	Unclear	Low	Low	Low
Ruppert-Kohlmayr 2004	High	Unclear	Unclear	Low	Low	Low	Low
Sasiwomonphan 2012	Unclear	Unclear	Unclear	Unclear	Low	Low	Low
Shebel 2011	Unclear	Unclear	Unclear	Low	Low	Low	Low
Sokhi 2015	Unclear	Low	Unclear	Unclear	Low	Low	Low
Song 2009	Unclear	Unclear	Unclear	Unclear	Low	Low	Low
Sun 2009a	Unclear	Unclear	Low	Unclear	Low	Low	Low
Tamai 2005	Unclear	Unclear	Unclear	Low	Low	Low	Low
Taouli 2009	Low	Unclear	Unclear	Unclear	Low	Low	Low
Tsili 2013	High	Low	Unclear	Low	Low	Low	Low
Xu 2010	Unclear	Low	Unclear	Unclear	Low	Low	Low
Xue 2015	Low	Unclear	Unclear	Low	Low	Low	Low
Young 2013	Low	Unclear	Unclear	Unclear	Low	Low	Low
Yuan 2011	Low	Low	Low	Unclear	Low	Low	Low
Zhang 2012	Low	Low	Low	Low	Low	Low	Low




 High
  Unclear
  Low

Figure 1: Risk of bias assessment

2.5 Outcome measures and synthesis

The primary outcome measures assessed were accuracy, sensitivity, specificity, positive and negative predictive value (PPV/NPV) for diagnosing and staging RCC. Whenever possible, data was pooled and median sensitivity/specificity was calculated. Information was summarised by imaging modality and by similar populations examined (subgroup analysis). The subgroup analysis of small renal masses ≤ 4 cm (SRM) was pre-specified.

Based on the heterogeneity of data, a narrative synthesis had to be chosen over a quantitative analysis.

3. Findings

3.1 Study selection

Through database searching, 4593 abstracts matching our search items were identified. Out of these, 182 abstracts were selected for full text screening. As six articles were not possible to be retrieved, we ended up with 176 papers for full text screening. In total, 40 studies comprising 4354 patients were eligible for data abstraction and analysis.

Out of the 40 included studies, 22 were case series investigating only one imaging modality, while 18 were comparative studies, examining two or more different imaging techniques. 30 papers reported on trials examining diagnostic accuracy, while nine studies examined staging accuracy and one trial rated both diagnostic and staging accuracy. All of them were retrospective.

A flow chart displaying the process of study selection can be seen in figure 2.

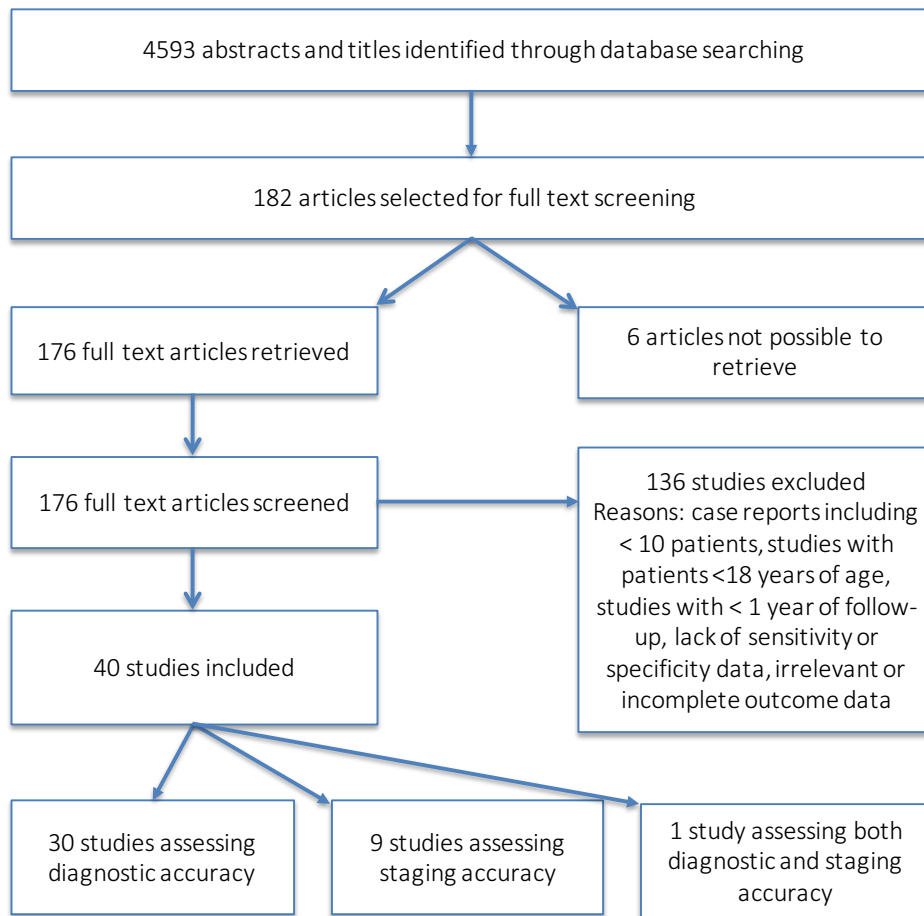


Figure 2: Study selection

3.2 Imaging

Overall, four major imaging modalities and their numerous variations were investigated in the 40 studies: CT, MRI, PET/CT and ultrasound. Contrast-enhanced CT as the traditional gold standard [17] for diagnosing renal cell cancer was studied in 23 articles. MRI was examined in twelve papers, using various different techniques such as diffusion-weighted, contrast-enhanced or blood oxygen level-dependent MRI. Ultrasound was also used in twelve studies, including CEUS, colour Doppler ultrasound and unenhanced conventional sonography. PET-CT was examined in four articles, using different tracers such as ^{18}F -FDG or ^{124}I -girentuximab.

Tables 1 and 2 give a summary of the characteristics of the included studies.

Table 1: Characteristics of included studies assessing diagnostic accuracy

Study	No. of pts.	Tumour size (cm) (mean)	Tumour subtypes	Reference standard	Intervention	Outcome: Diagnostic accuracy
Ak 2005	19	7.42±0.57	15 RCC 2 AML 2 others	histo-pathology	¹⁸ F-FDG PET/CT	Sensitivity: 86% Specificity: 75%
Chen 2015	99	1.81 ± 0.59 (all ≤ 3)	81 RCC 21 AML	histo-pathology	CEUS Conventional ultrasound	Sensitivity: 89% Specificity: 81% Sensitivity: 56% Specificity: 71%
Choi 2012	84	RCC: 2.74 ±0.65 benign: 2.41 ±0.73 (all ≤ 4)	67 RCC 6 AML 8 onco-cytomas 2 adenomas 1 cyst	histo-pathology	Quadriphasic multidetector helical CT	Sensitivity: 94% Specificity: 41%
Divgi 2013	195	NR	168 RCC 4 AML 16 onco-cytomas 1 adenoma 2 cysts 3 others	histo-pathology	¹²⁴ I-girentuximab PET/CT Multiphasic CECT	Sensitivity: 86% Specificity: 86% Sensitivity: 76% Specificity: 47%
Hindman 2012	108	RCC: 5.6 AML: 2.1	88 RCC 20 AML	histo-pathology	MRI	Sensitivity: 89% Specificity: 65%
Ho 2012	58	RCC: 4.8±3.5 AML: 3.3±1.7	50 RCC 16 AML	histo-pathology and/or follow-up for test-negatives	Dual tracer PET/CT	Sensitivity: 90% Specificity: 90%
Ignee 2010	143	RCC: 5.4±3.1 AML: 3.9±1.4	109 RCC 4 AML 1 onco-cytoma 1 adenoma 17 non-RCC malignant tumours 14 others	histo-pathology	CEUS	Sensitivity: 97% Specificity: 45%
Jiang 2008	26	4.3 (range 2.2-15.3)	15 RCC 11 cysts	histo-pathology and/or follow-up for test-negatives	CEUS PDUS CECT	Sensitivity: 100% Specificity: 64% Sensitivity: 47% Specificity: 55% Sensitivity: 67% Specificity: 67%

Kim 2002	110	5.7±2.5	110 RCC: 76 ccRCC 34 non-ccRCC	histo- pathology	CECT	Sensitivity: 74%/84% Specificity: 100%/91%
Kim 2009	41	3.9	26 RCC 38 cysts	histo- pathology and/or follow-up for test- negatives	DW MR CE MR	Sensitivity: 71% Specificity: 91% Sensitivity: 65% Specificity: 96%
Kim 2012	60	ccRCC: 2.81 ±0.74 non- ccRCC: 2.18 ±0.75 (all ≤ 4)	60 RCC: 42 ccRCC 18 non-ccRCC	histo- pathology	DCE MR	Sensitivity: 81%/76% Specificity: 88%/100%
Kim 2016	552	ccRCC: 2.8 pRCC: 3.1 chRCC: 3.3 AML: 2.6 (all ≤ 4)	512 RCC 51 AML	histo- pathology	Three-phase MDCT	Sensitivity: 85% Specificity: 84% (ccRCC vs. AML) Sensitivity: 88% Specificity: 92% (ccRCC vs. pRCC) Sensitivity: 74% Specificity: 79% (ccRCC vs. chRCC)
Kutman 2013	149	4.8±2.7	127 RCC 8 AML 14 onco- cytomas	histo- pathology	DCE CT	Sensitivity: 88% Specificity: 87%
Li 2011	72	all ≤4 (range 1- 4)	58 RCC 12 AML 2 onco- cytomas	histo- pathology	CEUS CECT	Sensitivity: 93% Specificity: 71% Sensitivity: 81% Specificity: 64%
Li 2013	91	3.3±1.7	85 RCC 13 AML 2 onco- cytomas	histo- pathology	CEUS Conven- tional ultrasound	Sensitivity: 93% Specificity: 97% Sensitivity: 60% Specificity: 73%
Lu 2015	192	ccRCC: 3.7 ± 1.8 pRCC: 3.5 ± 1.1 chRCC: 2.9 ± 0.9 AML: 4.1 ± 1.4	159 RCC 34 AML	histo- pathology	CEUS	Sensitivity 1: 96% Specificity 1: 95% (ccRCC vs. pRCC/ chRCC) Sensitivity 2: 90% Specificity 2: 96% (RCC vs. AML)
Notoha- miprodjo 2013	18	ccRCC: 5.6 ±2.5 pRCC: 4.1±1.4	18 RCC: 14 ccRCC 4 pRCC	histo- pathology	DW MRI	Sensitivity: 100% Specificity: 50%

					BOLD MRI	Sensitivity: 100%
					DCE MRI	Specificity: 33%
						Sensitivity: 100%
						Specificity: 75%
Pedrosa 2008	76	5.4 (range 1.1–15)	69 RCC: 48 ccRCC 15 pRCC 5 chRCC 1 unclassified RCC 10 others	histo- pathology	MRI	Sensitivity: 92%/80%
						Specificity: 83%/94%
Quaia 2008	40	4.3±2.2	21 RCC 18 cysts 1 cystic nephroma	histo- pathology and/or follow-up for test- negatives	CEUS	Sensitivity: 89%
					Unenhanced sonography	Specificity: 74%
					Multiphasic CECT	Sensitivity: 46%
						Specificity: 12%
Ruppert- Kohlmayr 2004	97	ccRCC: 5.9±4.8 pRCC: 2.5±1.1 (range 1.1–31)	NR (>107) RCC	histo- pathology	Triphasic CECT	Sensitivity: 98%/95%/95%/ 92%
						Specificity: 92%/92%/75%/ 69%
Sasiwi- monphan 2012	75	AML: 2.1 RCC: 2.4 (all ≤ 4)	71 RCC 10 AML	histo- pathology	MRI	Sensitivity: 73%
						Specificity: 99%
Shebel 2011	97	NR (range 2- 8)	79 RCC 4 AML 14 oncocytomas	histo- pathology	Quadriphasic multidetec- tor CT	Sensitivity: 98%/92%
						Specificity: 90%/90%
Song 2009	104	NR	56 RCC 48 cysts	histo- pathology	Multiphasic CECT	Sensitivity: 97%
						Specificity: 86%
Sun 2009	112	5.4 (range 1.1-19.5)	113 RCC: 75 ccRCC 28 pRCC 10 chRCC	histo- pathology	DCE MRI	Sensitivity: 93%
						Specificity: 96%
Tamai 2005	29	5.1±2.1	24 RCC 1 collecting duct carcinoma 1 urothelial carcinoma 1 AML 2 onco- cytomas	histo- pathology	CEUS	Sensitivity: 94%
					CECT	Specificity: 46%
						Sensitivity: 89%
						Specificity: 73%
Taouli 2009	64	4.2±2.5 (range 1.0–12.7)	28 RCC 62 cysts 10 AML 6 onco- cytomas 3 others	histo- pathology and/or follow-up for test- negatives	DW MRI	Sensitivity: 86%
					CE MRI	Specificity: 80%
						Sensitivity: 100%
						Specificity: 89%

					CE MRI + ADC information from DW MR	Sensitivity: NR Specificity: 96%
Xu 2010	109	RCC 4.2 AML 3.7 (range 1.5–11.7)	93 RCC 33 AML	histo- pathology and/or follow-up for test- negatives	CEUS	Sensitivity: 88% Specificity: 97%
Xue 2015	201	ccRCC: 3.64 ± 1.96 pRCC: 3.65 ± 2.04	205 RCC	histo- pathology	CEUS	Sensitivity: 53% Specificity: 97% (for prediction of pRCC)
Young 2013	274	4.2 (range 0.7–18.7)	249 RCC 49 onco- cytomas	histo- pathology	Quadri- phasic multide- tector CT	Sensitivity: 86%/94%/92% Specificity: 43%/62%/25%
Yuan 2011	87	3.2±2.4 (range 1.2-12)	73 RCC 14 AML	histo- pathology and/or follow-up for test- negatives	CEUS CECT	Sensitivity: 96% Specificity: 57% Sensitivity: 78% Specificity: 50%
Zhang 2012	30	NR	24 RCC 1 neuro- endocrine tumour 3 renal lymphomas 2 others	histo- pathology	¹⁸ F-FDG PET/CT	Sensitivity: 90% Specificity: 100%

Table 2: Characteristics of included studies assessing staging accuracy

Study	No. of pts.	Tumour size	Tumour subtypes	Reference standard	Endpoint examined	Intervention	Outcome: Staging accuracy
Hallscheidt 2004	58	NR	82 RCC 1 AML 1 onco- cytoma 1 cystic nephroma 4 urothe- lial carcinomas	histo- pathology	general staging	MRI Triphasic multi- detector CT	Sensitivity: 91%/89% Specificity: 83%/67% Sensitivity: 88%/86% Specificity: 72%/77%
Hallscheidt 2005	23	NR	23 RCC	histo- pathology	tumour thrombus	MRI Triphasic multi-	Sensitivity: 100%/85% Specificity: 75% Sensitivity: 93%

						detector CT	Specificity: 80%
Hedgire 2013	109	4.5 (median) (range 0.8-16.7)	109 RCC	histo-pathology	peri-nephric fat invasion	MRI Quadri-phasic CECT	Sensitivity: 72% Specificity: 93% Sensitivity: 84% Specificity: 56%
Ignee 2010	143	RCC: 5.4±3.1 AML 3.9±1.4	109 RCC 4 AML 1 onco-cytoma 1 adenoma 17 non-RCC malignant tumours 14 others	histo-pathology	renal vein invasion	CEUS CECT	Sensitivity: 83% Specificity: 96% Sensitivity: 42% Specificity: 98%
Karlo 2013a	186	5.3 (range 1.3–23.0)	188 RCC	histo-pathology	muscular venous branch invasion renal sinus fat invasion	MRI	Sensitivity: 100% Specificity: 42% Sensitivity: 100% Specificity: 94%
Karlo 2013b	261	3.8 (range 0.6–19.3)	258 RCC 3 non-RCC malignant tumours	histo-pathology	collecting system invasion	Triphasic CECT	Sensitivity: 100% Specificity: 100%
Karlo 2013c	115	4.2 (range 0.9–13.4)	103 RCC 6 onco-cytomas 2 others	histo-pathology	muscular venous branch invasion	Mono-phasic CECT	Sensitivity: 94% Specificity: 30%
Khan 2008	30	NR	30 RCC	histo-pathology	tumour thrombus	Colour Doppler ultrasound CECT	Sensitivity: 92% Specificity: 94% Sensitivity: 62% Specificity: 82%
Sokhi 2015	117	median 5.5 (range 0.9–19)	117 RCC	histo-pathology	renal sinus fat invasion peri-nephric fat invasion	Biphasic CECT	Sensitivity: 71%/88% Specificity: 79%/71% Sensitivity: 83%/68% Specificity:

					renal vein invasion		76%/72% Sensitivity: 59%/69% Specificity: 93%/91%
Tsili 2013	47	5.1 (range 1.2-15)	48 RCC	histo-pathology	peri-nephric fat invasion renal sinus fat invasion	Quadri-phasic multi-detector CT	Sensitivity: 69% Specificity: 71% Sensitivity: 97% Specificity: 43%

3.2.1 Contrast-enhanced CT

Twenty-three studies investigated the performance of contrast-enhanced CT (CECT) in the characterisation of renal masses.

As anticipated, diagnostic and staging accuracy values were very good, but in several cases they were exceeded by the values that other imaging modalities attained.

Overall, CECT displayed a very good median diagnostic sensitivity of 88% (IQR 81-94%) and a specificity of 75% (IQR 51-90%).

Twelve papers analysed the performance of CECT in the differentiation of RCC from other renal tumours [18-29].

Five of them [20, 23, 24, 27, 29] compared the diagnostic accuracy of CECT to that of CEUS and other ultrasound techniques. All of these revealed a superiority of CEUS in the characterisation of renal tumours. While CECT only reached a median sensitivity of 81% (IQR 72.5-87.5%) in these studies, CEUS was able to achieve 94% (IQR 91-98%). Regarding specificity though, values were equally poor with a median of 64% for both imaging modalities (IQR 50.5-70% for CECT and 51.5-72.5% for CEUS).

In comparison to power Doppler ultrasound [20] and conventional unenhanced sonography [24], CECT was superior though.

One multi-centre study [19] compared the diagnostic accuracy of contrast-enhanced CT to that of ¹²⁴I-girentuximab PET/CT. Analysing a large variety of different renal lesions in a large number of patients, CECT only reached a sensitivity of 76% and

specificity of 47%, while PET/CT achieved values of 86% and 86%.

Three studies [18, 21, 23] only included renal masses ≤ 4 cm in their analysis. All three studies displayed high sensitivity with a median of 85% (range 81-94%) combined with a mediocre median specificity of 64% (range 41-84%).

Another four studies [20, 24, 26, 30] analysed the diagnostic accuracy of CECT in complex cystic renal masses. The results were rather heterogeneous, with sensitivity values ranging from 67% [20] to 97% [26] and a median of 86%. In comparison to the performance of CEUS [20, 24, 30], CECT was inferior.

Finally, five studies [21, 25, 28, 31, 32] analysed the performance of CT in the discrimination of clear cell RCC (ccRCC) from other RCC subtypes. In the differentiation of ccRCC from papillary RCC (pRCC) they were able to provide a median sensitivity of 94.5% (IQR 91-95.75%) and specificity of 83.5% (IQR 67.25-92%) [21, 28, 31, 32]. Regarding the discrimination of ccRCC from chromophobe RCC (chRCC), a median sensitivity of 92% and specificity of 79% was reached [21, 25, 28]. For differentiating ccRCC from non-ccRCC in general, a median sensitivity and specificity of 79% and 95.5% was attained in one study [31].

Nine studies investigated the eligibility of CECT for staging RCC. In total, staging accuracy was very good.

General staging sensitivity [33] reached a median of 87% (88% and 86% for two different readers) and a median specificity of 74.5% (72%/77%). For the detection of tumour thrombus [34, 35], median sensitivity was 77.5% and specificity 81%. Compared to MRI, accuracy was inferior though in this respect [34]. Concerning perinephric fat invasion [36-38], CECT achieved a median sensitivity and specificity of 76% (IQR 68.25%-83.75%) and 71.5% (IQR 59.75%-71.5%). For renal vein invasion [30, 38] sensitivity was poor (median: 59%), while specificity reached a median of 93%. In contrast, for muscular venous branch invasion [39], sensitivity was excellent (94%) while specificity was very poor (30%). Regarding renal sinus fat invasion two studies [37, 38] reported a median sensitivity of 88% and specificity of 71%. In the detection of collecting system invasion, both sensitivity and specificity even reached 100% in one study [40].

Table 3: CT - Summary of diagnostic accuracy

Study	Intervention	Sensitivity	Specificity
Choi 2012	Quadriphasic multidetector helical CT	94%	41%
Divgi 2013	Multiphasic contrast-enhanced CT	76%	47%
Jiang 2008	Contrast-enhanced CT	67%	67%
Kim 2002	Contrast-enhanced CT	74% 84%	100% 91%
Kim 2016	Three-phase MDCT	85% 88% 74%	84% 92% 79%
Kutman 2013	Dynamic contrast enhanced CT	88%	87%
Li 2011	Contrast-enhanced CT	81%	64%
Quaia 2008	Multiphasic contrast-enhanced CT	86%	51%
Ruppert-Kohlmayr 2004	Triphasic contrast-enhanced CT	98% 95% 95% 92%	92% 92% 75% 69%
Shebel 2011	Quadriphasic multidetector CT	98% 92%	90% 90%
Song 2009	Multiphasic contrast-enhanced CT	97%	86%
Tamai 2005	Contrast-enhanced CT	89%	73%
Young 2013	Quadriphasic multidetector CT	86% 94% 92%	43% 62% 25%
Yuan 2011	Contrast-enhanced CT	78%	50%
Median (+/- IQR)		88% (81-94%)	75% (51-90%)

3.2.2 MRI

Twelve studies investigated the diagnostic and staging accuracy of MRI for RCC [33, 34, 36, 41-49].

Various different imaging modes were used, such as diffusion-weighted (DW), dynamic contrast-enhanced (DCE) and blood oxygen level-dependent (BOLD) MRI as well as a combination of different techniques. On the whole, MRI had very high diagnostic accuracy values, with a median sensitivity of 87.5% (IQR 75.25-100%) and specificity of 89% (IQR 75-96%).

Four studies [41, 42, 46, 48] investigated the performance of MRI in the

discrimination between RCC and other renal tumours.

Two of them [41, 46] used MRI to differentiate between RCC and AML with minimal fat. They achieved a median sensitivity of 81% (range 73-89%) and specificity of 82% (range 65-99%) respectively. The lower sensitivity in the second study combined with the higher specificity could be due to the fact that only renal masses ≤ 4 cm were included.

Another one [48] compared DW MRI, CE MRI and a combination of both in the diagnosis of RCC. CE MRI was slightly superior to DW MRI with a sensitivity of 100% and a specificity of 89% (values were 86% and 80% for DW MRI). The combination of CE MRI with the apparent diffusion coefficient (ADC) information from DW MRI was able to increase specificity to 96%.

The last one of them [42] compared the eligibility of ADC measurement in DW MRI with that of contrast-enhanced MRI in the differentiation of T1 hyperintense renal lesions. DW MRI was able to reach a sensitivity of 71% and a specificity of 91%, while CE MRI rendered a sensitivity of 65% and a specificity of 96%.

Another four studies [43-45, 47] examined the ability to differentiate between different RCC subtypes on MRI.

One of them [44] compared the eligibility of diffusion-weighted (DW), blood oxygen level-dependent (BOLD) and dynamic contrast-enhanced (DCE) MRI in the differentiation of ccRCC from pRCC. All three modes were able to achieve a sensitivity of 100% with varying specificity values. DCE MRI achieved the highest diagnostic accuracy with a specificity of 75%. DW and BOLD MRI only reached poor specificities of 50% and 33% respectively. However, the number of patients included in the study was very low with only 18 participants.

A second study [47] that used DCE MRI to differentiate ccRCC from pRCC attained sensitivity and specificity values of 83% and 89%.

Similarly, in the discrimination of ccRCC and non-ccRCC in small renal masses ≤ 4 cm DCE MR yielded good diagnostic accuracy values with a sensitivity of 81% and a specificity of 88% [43].

The final four studies investigated the usefulness of MRI in staging RCC.

Regarding general staging of RCC [33], MRI was able to achieve an excellent median sensitivity of 90% (91% and 89% for two different readers) that even surpassed that

of multidetector CT with 87% (88%/86%). Specificity was lower though with a median of 75% (83%/67%).

For the detection of perinephric fat invasion [36], MRI reached a sensitivity of 72% and a specificity of 93%. In the identification of renal sinus fat invasion and muscular venous branch invasion [49] sensitivity values of 100% were achieved. For muscular venous branch invasion specificity was poor though with only 42%.

Table 4: MRI - Summary of diagnostic accuracy

Study	Intervention	Sensitivity	Specificity
Hindman 2012	MRI (standard techniques)	89%	65%
Kim 2009	Diffusion-weighted MR Contrast-enhanced MR	71%	91%
		65%	96%
Kim 2012	Dynamic contrast-enhanced MR	81%	88%
		76%	100%
Notohamiprodjo 2013	Diffusion-weighted MRI	100%	50%
	Blood oxygen level-dependent MRI (BOLD)	100%	33%
	Dynamic contrast-enhanced MRI	100%	75%
Pedrosa 2008	MRI	92%	83%
		80%	94%
Sasiwimonphan 2012	MRI	73%	99%
Sun 2009	Dynamic contrast-enhanced MRI	93%	96%
Taouli 2009	Diffusion-weighted MRI	86%	80%
	Contrast-enhanced MRI	100%	89%
	CE MRI + ADC information from DW MR	NR	96%
Median (+/- IQR)		87.5% (75.25-100%)	89% (75-96%)

3.2.3 Ultrasound

3.2.3.1 Unenhanced sonography

Three studies [24, 50, 51] compared the diagnostic value of unenhanced conventional ultrasound to CEUS and/or CECT. All of them reported very poor diagnostic accuracy values for the diagnosis of RCC with a median sensitivity of 56% (range 46-60%) and specificity of 71% (range 12-73%). Especially in the diagnosis of malignancy in complex renal cysts, sensitivity and specificity of unenhanced

sonography were extremely poor (46% and 12%) [24]. In differentiating RCC from AML and oncocytoma, diagnostic accuracy was slightly better with a median sensitivity of 58% and specificity of 72%, but still far from the values that were reached with CEUS and CECT [50, 51].

Table 5: Unenhanced sonography - Summary of diagnostic accuracy

Study	Intervention	Sensitivity	Specificity
Chen 2015	Unenhanced sonography	56%	71%
Li 2013	Unenhanced sonography	60%	73%
Quaia 20008	Unenhanced sonography	46%	12%
Median		56%	71%

3.2.3.2 Colour Doppler ultrasound

One paper [20] compared the accuracy of power Doppler ultrasound to that of CEUS and CECT in differentiating complex renal cysts from cystic RCC. Both sensitivity and specificity were rather poor with values of 47% and 55% and were not able to keep up with the values achieved by the other imaging modalities.

Another article [35] examined the value of conventional colour Doppler in detecting venous tumour thrombus in RCC. For this indication, colour Doppler appeared to be a very useful tool with excellent sensitivity and specificity of 96% and 95% that even exceeded values reached by CECT.

Both studies had rather small sample sizes though with only 26 and 30 patients respectively.

3.2.3.3 Contrast-enhanced ultrasound (CEUS)

The value of CEUS in the characterisation of renal masses was examined in eleven studies [20, 23, 24, 27, 29, 30, 50-54].

All in all, CEUS was able to achieve excellent sensitivity values combined with mediocre specificity. Specificity values were rather heterogeneous with a median of 72.5% (IQR 54-97%). In contrast, median sensitivity reached 93% (IQR 88.75-98.25%).

Three studies [20, 24, 30] found CEUS to be superior to CECT also in the subgroup of complex cystic renal masses with a median sensitivity of 94.5% and specificity of 69% (CT: 86% and 67%).

Likewise, for small renal tumours ≤ 4 cm CEUS achieved a median sensitivity of 91% and specificity of 76% [23, 51], whereas CT only reached 85% and 64% [18, 21, 23]. Furthermore, in the differentiation of RCC from AML CEUS reached very high median sensitivity and specificity values of 89% and 96% [51-53].

One study [54] examined CEUS in the prediction of papillary RCC (pRCC), reaching a mediocre sensitivity of 53% combined with excellent specificity (97%).

Another study [30] investigated CEUS in the detection of renal vein invasion. In a population with 12 patients displaying renal vein invasion out of 106 patients with RCC, CEUS was able to achieve sensitivity and specificity values of 83% and 96% respectively.

Table 6: CEUS - Summary of diagnostic accuracy

Study	Intervention	Sensitivity	Specificity
Chen 2015	CEUS	89%	81%
Ignee 2010	CEUS	97%	45%
Jiang 2008	CEUS	100%	64%
Li 2011	CEUS	93%	71%
Li 2013	CEUS	93%	97%
Quaia 2008	CEUS	89%	74%
Tamai 2005	CEUS	94%	46%
Xu 2010	CEUS	88%	97%
Xue 2015	CEUS	53%	97%
Yuan 2011	CEUS	96%	57%
Median (+/- IQR)		93% (88.75 - 98.25%)	72.5% (54 - 97%)

3.2.4 PET/CT

The use of PET/CT in the characterisation of renal masses was evaluated in four different studies [19, 55-57]. They all reported high diagnostic accuracy for the differentiation of RCC from other benign and malignant renal masses.

Two studies [55, 57] used ^{18}F -FDG as a tracer. They reported a median sensitivity of 88% (range 86%-90%) and specificity of 87.5% (range 75%-100%). Size and grade of

FDG-positive tumours was found to be higher than those of FDG-negative lesions. However, sample sizes were low with 19 and 30 patients respectively.

One multi-centre study [19] compared the diagnostic accuracy of ¹²⁴I-girentuximab PET/CT with that of contrast-enhanced CT. Recruiting a large population of 195 patients with a wide variety of renal tumours, PET/CT was able to attain sensitivity and specificity values of 86% and 86%.

For the differentiation of RCC and angiomyolipoma, another study [56] achieved excellent diagnostic accuracy values using ¹⁸F-FDG and ¹¹C-acetate for dual-tracer PET/CT. All AML showed negative ¹⁸F-FDG but increased ¹¹C-acetate metabolism that was significantly higher than RCC. Overall, sensitivity and specificity for the detection of RCC both reached 90%. For the diagnosis of angiomyolipoma diagnostic accuracy values even reached 97%. Furthermore, different RCC subtypes could be differentiated due to their different dual-tracer metabolic patterns.

Table 7: ¹⁸F-FDG-PET/CT - Summary of diagnostic accuracy

Study	Intervention	Sensitivity	Specificity
Ak 2005	¹⁸ F-FDG-PET/CT	86%	75%
Zhang 2012	¹⁸ F-FDG-PET/CT	90%	100%
Median		88%	87.5%

3.3 Subgroup analysis

A number of studies focused on specific questions within the broad topic of characterisation of renal masses. Some only included certain kinds of tumours, such as small renal masses or complex cystic renal masses. Others specifically investigated the differentiation of RCC from AML. Still others examined specific aspects concerning the staging of RCC.

3.3.1 Small renal masses

Six studies [18, 21, 23, 43, 46, 51] examined the diagnostic performance of CECT, CEUS and MRI in the differentiation of small renal masses (SRM) ≤ 4 cm. CECT was

able to achieve a high median sensitivity of 85% (IQR 77.5-91%) but only moderate median specificity of 79% (IQR 52.5-88%) [18, 21, 23]. In contrast, MRI yielded higher specificity values with a median of 99% (range 88%-100%) [43, 46], combined with lower sensitivity (median 76%, range 73%-81%). CEUS was used in two studies [23, 51] that rendered excellent sensitivity (median 91%) but lower specificity (median 76%).

3.3.2 Complex cystic renal masses

Another four studies [20, 24, 26, 30] reported on the characterisation of cystic renal masses. Three of them [20, 24, 30] compared the diagnostic accuracy of CEUS to that of CECT and/or power Doppler ultrasound (PDUS) and unenhanced sonography. One of them [26] only examined the use of CECT in the differential diagnosis of cystic renal masses without comparing it to CEUS. The papers examining CEUS stated excellent sensitivity values with a median of 94.5% (range 89%-100%) for CEUS that were superior to those of CECT (median: 86%, range 67%-97%). Median specificity was equally lower though with 69% (64%-74%) for CEUS and 67% (range 51%-86%) for CECT.

In contrast, diagnostic accuracy for PDUS and unenhanced sonography were poor [20, 24].

3.3.3 Differentiation of renal cell carcinoma from angiomyolipoma

The discrimination of RCC from AML in particular was investigated in six articles [41, 46, 51-53, 56]. Overall, they were able to yield good results with all the imaging modalities that were used: MRI, PET/CT and CEUS.

The two studies examining MR only included AML with minimal fat. Accuracy values displayed quite a broad range with a median sensitivity of 81% (range 73%-89%) and specificity of 82% (range 65%-99%) [41, 46].

For PET/CT diagnostic accuracy was slightly higher with a sensitivity of 90% and a specificity of 90% [56]. Similarly, for CEUS, median sensitivity and specificity reached 89% and 96% [51-53] in this set-up. However, the slightly higher accuracy values for

PET/CT and CEUS could be due to the fact that not just fat-free AML were included.

3.4 Staging of RCC

Ten studies focused on questions concerning the staging of RCC [30, 33-40, 49].

One of them [33] examined the use of MRI and CECT for the general staging of RCC. Both imaging techniques achieved good results with a median sensitivity of 87% (88% and 86% for two different readers) and specificity of 74.5% (72%/77%) for CT and a median sensitivity of 90% (91%/89%) and specificity of 75% (83%/67%) using MRI.

Two articles [34, 35] investigated the detection of tumour thrombus in RCC using CECT, MRI and colour Doppler ultrasound. CECT was used in both studies, but yielded varying results with a median sensitivity of 77.5% (range 62-93%) and specificity of 81% (range 80-82%). MRI was able to attain a median sensitivity of 92.5% (85% and 100% for two different readers), but with slightly lower specificity of 75% [34]. However, colour Doppler ultrasound was superior to both MRI and CECT with a sensitivity of 96% and specificity of 95% [35].

Seven of the studies [30, 36-40, 49] examined the invasion of structures adjacent to the kidneys, such as perinephric fat, collecting system, renal vein or renal sinus fat. Regarding perinephric fat invasion, three studies [36-38] found CECT to provide satisfactory median sensitivity of 76% (IQR 68.25%-83.75%) and specificity of 71.5% (IQR 59.75%-71.5%). MRI was able to yield similar sensitivity (72%) but higher specificity (93%) [36].

Concerning muscular venous branch invasion, two studies [39, 49] reported excellent sensitivity for both CECT (94%) [39] and MRI (100%) [49] combined with poor specificity (30% vs. 42%).

Using CECT for the diagnosis of collecting system invasion, one study [40] even stated diagnostic accuracy values of 100%.

In the diagnosis of renal vein invasion, two studies [30, 38] found CEUS to be superior to CECT concerning sensitivity (83% vs. median of 59%), while specificity values were almost identical (96% vs. median of 93%).

Regarding sinus fat invasion, two papers [37, 38] reported high sensitivity (median 88%) along with mediocre specificity (median 71%) for CECT, whereas MRI achieved a sensitivity of 100% and specificity of 94% in one study [49].

3.5 Risk of bias

Quality and risk of bias of the included studies was assessed using the QUADAS-2 tool [16]. QUADAS-2 is composed of four domains including patient selection, index test, reference standard and flow and timing. A summary of the results can be seen in figure 2.

Overall, there was a large number of cases of unclear risk of bias, where information needed for the assessment was not mentioned by the studies. For the reference standard in particular, only few studies reported whether the test results were interpreted without knowledge of the index test. Even though this may seem unlikely in most cases, we were only able to rate the risk of bias “unclear” in this domain for these papers.

However, apart from these uncertain cases, risk of bias was rather low across studies. In the domains of index test, reference standard and flow and timing there were no instances of high risk of bias at all. The few cases that were rated to be at high risk of bias resulted from ambiguities in patient selection. These articles did not clarify whether a consecutive or random sample of patients was included and if inappropriate exclusions were avoided.

There were no concerns regarding applicability in any of the domains, probably owing to the consistent application of inclusion and exclusion criteria in the process of study selection.

4. Discussion

4.1 Summary of evidence

According to the current EAU guidelines on renal cell carcinoma ultrasound, CT and MRI are the traditional imaging techniques for the characterisation of renal masses and diagnosis of RCC. In most cases, renal masses are found incidentally on ultrasound or CT and are then further evaluated by contrast-enhanced CT. If there are any contraindications to CT or if the CT results are indeterminate, MRI is used for further analysis [6].

In summary, this approach is substantiated by the results of our systematic review. Both CT and MRI achieved very high diagnostic and staging accuracy for RCC and a number of other renal tumours. Overall median sensitivity for the diagnosis of RCC reached 88% (IQR 81-94%) for CT and 87.5% (IQR 75.25-100%) for MRI. The median specificity of MRI even exceeded that of CT with 89% (IQR 75%-96%) vs. 75% (IQR 51%-90%). This may justify the use of MRI in cases of indeterminate imaging results of CT.

As for the staging of RCC, both imaging modalities rendered high accuracy values, as well. For CT, median staging sensitivity and specificity were 87% and 74.5%, while MRI reached a median sensitivity of 90% and specificity of 75%. However, for more specific questions concerning the staging and exact determination of the tumour spread, different imaging techniques may be useful depending on the aspect examined.

For ultrasound, the results varied strongly depending on the corresponding technique. CEUS was able to achieve excellent overall diagnostic sensitivity with a median of 93% (IQR 88.75%-98.25%) in combination with mediocre median specificity (72.5%, IQR 54%-97%). In the subgroup of complex cystic renal masses, CEUS proved to be even superior to CECT with a median sensitivity of 94.5% and specificity of 69% (vs. 86% and 67% for CECT). Furthermore, CEUS appeared to be useful in the detection of renal vein invasion.

The diagnostic performance of unenhanced sonography was poor. However, it has

to be kept in mind that the majority of incidental renal masses are first detected on ultrasound despite its modest accuracy [17]. Yet, for the further evaluation of these incidental masses other imaging modalities are required.

For PET/CT diagnostic accuracy values were good, but based on only a small amount of data available. Here, further research needs to be done in order to draw any solid conclusions. At the same time, the high radiation exposure of PET/CT has to be taken into account.

The subgroup analyses we performed displayed high sensitivity for CEUS and CECT in the characterisation of small renal masses combined with lower specificity. The highest specificity values in this subgroup was yielded by MRI. These results suggest that a combination of imaging methods may be useful in the differentiation of SRM, but no data exist if this combination would lead to a higher specificity and a change in the workup of patients.

4.2 Strengths and limitations of the review

The implementation of this systematic review adheres to the PRISMA guidelines [14] and Cochrane review on diagnostic test accuracy principles [58]. It summarises the best available evidence on imaging methods for the diagnosis and staging of RCC. The PICO (population, intervention, comparison and outcomes) elements of the research question were developed by an expert panel of urologists (EAU RCC Guideline Panel). The strict methodology of the entire review makes the results reliable, reproducible and transparent.

However, there is a number of limitations to the review. The strong heterogeneity of data confined us to a narrative synthesis of the results, making a meta-analysis impossible. All of the included studies were retrospective. About half of them were case series only examining one imaging modality, the other half were comparative studies. Many of the studies had relatively small sample sizes. Due to the incomplete retrieval of the selected abstracts and the limitation of the search to studies from 2000 onwards, important publications might have been missed. There is a certain potential for selection bias in the process of study selection and for differential-

verification bias due to variations in the reference standard (e.g. different follow-up protocols). For some imaging modalities such as PET/CT and colour Doppler ultrasound there was only a small number of studies available. There were many cases of unclear risk of bias due to the lack of information on certain practices of the included studies. Hardly any of the studies provided information on the influence of imaging results on therapeutic interventions or overall survival, which restricts the potential to give clinical recommendations based on the results of the studies.

4.3 Factors influencing diagnostic confidence

Furthermore, there are various factors that influence the reliability of the results of each included study.

First of all, there is a huge variety of different scanners, sequences, techniques, imaging protocols, contrast mediums and technical equipment that influences the quality of the images. For example, the heterogeneous group of studies investigating MRI comprises diffusion-weighted (DW), contrast-enhanced (CE), dynamic contrast-enhanced (DCE), blood oxygen level dependent (BOLD) MRI and various standard MR techniques. Studies examining contrast-enhanced CT used monophasic, biphasic, triphasic or quadriphasic techniques with single- or multidetector scanners. This heterogeneity of data makes it hard to draw general conclusions.

Secondly, the diagnostic yield is influenced by histologic features of the tumour. Different studies also included different subgroups of benign and malignant renal masses, focusing on different aspects and challenges in the imaging of renal masses. Some studies focused on the differentiation of different subtypes of RCC, whereas others examined the accuracy for differentiating RCC from certain types of benign renal tumours such as AML or from all kinds of benign renal tumours. Depending on whether “difficult” differential diagnoses such as oncocytoma and AML with minimal fat were included or not, diagnostic accuracy varied. As Choudhary et al. [59] and Israel et al. [13] have stated, renal cell carcinoma cannot be reliably differentiated from oncocytoma and non-fat-containing angiomyolipoma.

Thirdly, the accuracy depends on the clinical experience as well as on the physical

and psychological state of the reader [60]. Even though inter-rater agreement was good across studies, differences in interpretation of imaging features remain. This is of particular interest in newer ultrasound techniques such as CEUS, which are mostly conducted by internists or urologists themselves. As Seppala et al. have indicated, diagnostic confidence increases with the experience of the clinician [61].

4.4 Contraindications and side effects

Moreover, not every imaging technique is suitable for any patient. Contraindications for contrast-enhanced CT include allergies to contrast medium, pregnancy and thyroid carcinoma. But also for MRI certain risks and contraindications have to be considered. Apart from the interaction with pacemakers and all kinds of ferromagnetic metals, the potential side effect of gadolinium contrast-associated nephrogenic systemic fibrosis needs to be kept in mind [62]. Generally, awareness of the high radiation exposure not only of CT, but even more so of PET/CT is crucial whenever the indication for further imaging is introduced.

5. Conclusions

Contrast-enhanced CT and MRI remain the diagnostic mainstay for renal cell carcinoma with almost equally high diagnostic and staging accuracy. Furthermore, there is evidence for an increasing significance of CEUS in the future, particularly in the subgroup of complex cystic renal masses. A combination of CT and CEUS or MRI and CEUS can be useful in the differential diagnosis of unclear renal tumours. Despite the poor diagnostic accuracy of unenhanced sonography, many renal masses are discovered incidentally on ultrasound. Further research is required on the role of PET/CT in the characterisation of renal masses.

However, because of the moderate methodological quality of many of the current studies, there is a need for future well-designed large prospective studies on the imaging in renal masses in order to further increase the quality of evidence.

Summary

While the incidence of renal cell carcinoma is rising in most countries of the world, stabilisation or even decrease of mortality has been accomplished in many countries of Europe and North America [1]. This can be explained by a growing number of incidentally detected renal masses as well as the availability of improved therapeutic measures in many Western countries [1, 3]. However, for treatment planning an accurate diagnosis is essential.

The aim of this review is to systematically assess the diagnostic performance of contrast-enhanced CT in comparison to other imaging modalities for diagnosing and staging RCC in adults. Through comprehensive database searching, 4593 abstracts matching the search items were identified. Out of these, 40 studies comprising 4354 patients were selected for data extraction and analysis. They examined four major imaging modalities and their numerous variations: CT, MRI, PET/CT and ultrasound. In summary, both CT and MRI yielded high diagnostic and staging accuracy values. For ultrasound, the results varied strongly depending on the corresponding technique. CEUS was able to achieve excellent overall diagnostic sensitivity while the diagnostic performance of unenhanced sonography was poor. For PET/CT diagnostic accuracy values were good, but based on only a small amount of data available. For more specific questions a combination of different imaging techniques such as CT or MRI and CEUS may be useful.

However, there is a number of limitations to the review. All of the included studies were retrospective and about half of them were case series, examining only one imaging modality. There is a strong heterogeneity of data due to the large variety in imaging techniques and tumour histotypes, which made it hard to draw any general conclusions. Hence, there is a need for future well-designed large prospective studies on the imaging in renal masses in order to further increase the quality of evidence.

Zusammenfassung

Bei weltweit steigender Inzidenz des Nierenzellkarzinoms konnte in vielen Ländern Europas und Nordamerikas eine Stabilisierung oder sogar ein Rückgang der Mortalität erzielt werden [1]. Grund dafür ist eine wachsende Anzahl inzidentell diagnostizierter renaler Raumforderungen bei gleichzeitiger Verfügbarkeit besserer therapeutischer Möglichkeiten [1, 3]. Für die Therapieplanung ist eine präzise Diagnosestellung jedoch unerlässlich.

Ziel dieses Reviews ist es, die diagnostische Leistung von Kontrastmittel-CT in der Diagnostik sowie im Staging des Nierenzellkarzinoms beim Erwachsenen im Vergleich mit anderen bildgebenden Modalitäten systematisch auszuwerten.

Durch eine umfassende Literaturrecherche in elektronischen Datenbanken konnten 4593 zu unseren Suchkriterien passende Abstracts identifiziert werden. Aus diesen wurden 40 Studien mit insgesamt 4354 Patienten zur Datenextraktion und Analyse ausgewählt. Sie untersuchten vier Haupt-Bildgebungsmodalitäten: CT, MRT, PET/CT und Ultraschall.

Zusammenfassend erbrachten sowohl CT als auch MRT beide eine ausgezeichnete Treffsicherheit sowohl in Bezug auf Diagnosestellung als auch bezüglich Staging. Im Hinblick auf die Untersuchungen mittels Ultraschall zeigte sich eine hohe Variabilität der Ergebnisse in Abhängigkeit von der verwendeten Untersuchungstechnik. Der kontrastmittelgestützte Ultraschall konnte eine exzellente diagnostische Sensitivität erreichen, wohingegen die konventionelle Sonographie eine eher schwache diagnostische Reliabilität zeigte. PET/CT erreichte eine gute diagnostische Sensitivität und Spezifität, die jedoch auf einer relativ geringen Anzahl von Studien beruhen. Für spezielle Fragestellungen kann auch die Kombination verschiedener Bildgebungen sinnvoll sein, insbesondere die von CT oder MRT mit der Kontrastmittel-Sonographie.

Es gilt jedoch zu bedenken, dass der Review einige Limitierungen aufweist. Alle eingeschlossenen Studien waren retrospektiv und bei etwa der Hälfte handelt es sich um Fallserien mit nur einer Art von Bildgebung. Allgemeine Schlussfolgerungen wurden durch die starke Heterogenität der Daten aufgrund der großen Vielfalt an

Bildgebungstechniken und Tumorhistologien erschwert. Es besteht daher ein umfangreicher Bedarf an zukünftigen großen prospektiven Studien, um die Qualität der Evidenz weiter zu verbessern.

Bibliography

1. Znaor, A., et al., *International variations and trends in renal cell carcinoma incidence and mortality*. Eur Urol, 2015. **67**(3): p. 519-30.
2. Tsui, K.H., et al., *Renal cell carcinoma: prognostic significance of incidentally detected tumors*. J Urol, 2000. **163**(2): p. 426-30.
3. Jayson, M. and H. Sanders, *Increased incidence of serendipitously discovered renal cell carcinoma*. Urology, 1998. **51**(2): p. 203-5.
4. Ferlay, J., et al., *Cancer incidence and mortality worldwide: sources, methods and major patterns in GLOBOCAN 2012*. Int J Cancer, 2015. **136**(5): p. E359-86.
5. Eble, J.N., et al., *Pathology and genetics of tumours of the urinary system and male genital organs. World Health Organization Classification of Tumours*. IARC Press, 2004.
6. Ljungberg, B., et al., *Guidelines on Renal Cell Carcinoma*. 2015, European Association of Urology.
7. Lipworth, L., R.E. Tarone, and J.K. McLaughlin, *The epidemiology of renal cell carcinoma*. J Urol, 2006. **176**(6 Pt 1): p. 2353-8.
8. Bellocco, R., et al., *Alcohol drinking and risk of renal cell carcinoma: results of a meta-analysis*. Ann Oncol, 2012. **23**(9): p. 2235-44.
9. Lee, C.T., et al., *Mode of presentation of renal cell carcinoma provides prognostic information*. Urol Oncol, 2002. **7**(4): p. 135-40.
10. Ljungberg, B., et al., *EAU guidelines on renal cell carcinoma: 2014 update*. Eur Urol, 2015. **67**(5): p. 913-24.
11. Wahlgren, T., et al., *Treatment and overall survival in renal cell carcinoma: a Swedish population-based study (2000-2008)*. Br J Cancer, 2013. **108**(7): p. 1541-9.
12. Schachter, L.R., et al., *Second prize: frequency of benign renal cortical tumors and histologic subtypes based on size in a contemporary series: what to tell our patients*. J Endourol, 2007. **21**(8): p. 819-23.
13. Israel, G.M. and M.A. Bosniak, *Pitfalls in renal mass evaluation and how to avoid them*. Radiographics, 2008. **28**(5): p. 1325-38.
14. Moher, D., et al., *Preferred reporting items for systematic reviews and meta-analyses: the PRISMA statement*. J Clin Epidemiol, 2009. **62**(10): p. 1006-12.
15. Macaskill P, G.C., Deeks JJ, Harbord RM, Takwoingi Y, *Chapter 10: Analysing and Presenting Results*, in *Cochrane Handbook for Systematic Reviews of Diagnostic Test Accuracy Version 1.0*, B.P. Deeks JJ, Gatsonis C, Editor. 2010, The Cochrane Collaboration.
16. Whiting, P.F., et al., *QUADAS-2: a revised tool for the quality assessment of diagnostic accuracy studies*. Ann Intern Med, 2011. **155**(8): p. 529-36.
17. Schneider, F., et al., *Diagnostik des Nierenzellkarzinoms*. Der Nephrologe, 2011. **4**: p. 306-311.
18. Choi, S.K., S.H. Jeon, and S.G. Chang, *Characterization of small renal masses less than 4 cm with quadruphase multidetector helical computed tomography: differentiation of benign and malignant lesions*. Korean J Urol, 2012. **53**(3): p. 159-64.
19. Divgi, C.R., et al., *Positron emission tomography/computed tomography identification of clear cell renal cell carcinoma: results from the REDECT trial*. J Clin Oncol, 2013. **31**(2): p. 187-94.
20. Jiang, J., Y. Chen, and Y. Zhou, *Contrast-enhanced ultrasonography of cystic renal cell carcinomas: compared with contrast-enhanced CT*. Chin J Med Imaging Technol, 2008. **24**(10): p. 1628-1631.
21. Kim, S.H., et al., *Differentiation of Clear Cell Renal Cell Carcinoma From Other Subtypes and Fat-Poor Angiomyolipoma by Use of Quantitative Enhancement Measurement During Three-Phase MDCT*. AJR Am J Roentgenol, 2016. **206**(1): p. W21-8.
22. Kutman, K., et al., *Is there a role of the enhancement degree of the lesion on computerized tomography for the characterization of renal tumors?* J Urol, 2013. **189**(2): p. 436-40.
23. Li, C., et al., *The value of contrast-enhanced ultrasound in the diagnosis of renal tumors equal to or smaller than 4 cm*. 2011.

24. Quaia, E., et al., *Comparison of contrast-enhanced sonography with unenhanced sonography and contrast-enhanced CT in the diagnosis of malignancy in complex cystic renal masses*. AJR Am J Roentgenol, 2008. **191**(4): p. 1239-49.
25. Shebel, H.M., et al., *Quantitative enhancement washout analysis of solid cortical renal masses using multidetector computed tomography*. J Comput Assist Tomogr, 2011. **35**(3): p. 337-42.
26. Song, C., et al., *Differential diagnosis of complex cystic renal mass using multiphase computerized tomography*. J Urol, 2009. **181**(6): p. 2446-50.
27. Tamai, H., et al., *Contrast-enhanced ultrasonography in the diagnosis of solid renal tumors*. J Ultrasound Med, 2005. **24**(12): p. 1635-40.
28. Young, J.R., et al., *Clear cell renal cell carcinoma: discrimination from other renal cell carcinoma subtypes and oncocytoma at multiphasic multidetector CT*. Radiology, 2013. **267**(2): p. 444-53.
29. Yuan, X., et al., *Comparison on contrast-enhanced ultrasonography and CT in diagnosing renal cell carcinoma*. Chin J Med Imaging Technol, 2011. **27**(12): p. 2502-2505.
30. Ignee, A., et al., *The value of contrast enhanced ultrasound (CEUS) in the characterisation of patients with renal masses*. Clin Hemorheol Microcirc, 2010. **46**(4): p. 275-90.
31. Kim, J.K., et al., *Differentiation of subtypes of renal cell carcinoma on helical CT scans*. AJR Am J Roentgenol, 2002. **178**(6): p. 1499-506.
32. Ruppert-Kohlmayr, A.J., et al., *Differentiation of renal clear cell carcinoma and renal papillary carcinoma using quantitative CT enhancement parameters*. AJR Am J Roentgenol, 2004. **183**(5): p. 1387-91.
33. Hallscheidt, P.J., et al., *Diagnostic accuracy of staging renal cell carcinomas using multidetector-row computed tomography and magnetic resonance imaging: a prospective study with histopathologic correlation*. J Comput Assist Tomogr, 2004. **28**(3): p. 333-9.
34. Hallscheidt, P.J., et al., *Preoperative staging of renal cell carcinoma with inferior vena cava thrombus using multidetector CT and MRI: prospective study with histopathological correlation*. J Comput Assist Tomogr, 2005. **29**(1): p. 64-8.
35. Khan, A.R., et al., *Comparison of CT scan and colour flow Doppler ultrasound in detecting venous tumour thrombosis in renal cell carcinoma*. J Ayub Med Coll Abbottabad, 2008. **20**(3): p. 47-50.
36. Hedgire, S.S., et al., *Preoperative evaluation of perinephric fat invasion in patients with renal cell carcinoma: correlation with pathological findings*. Clin Imaging, 2013. **37**(1): p. 91-6.
37. Tsili, A.C., et al., *Perirenal fat invasion on renal cell carcinoma: evaluation with multidetector computed tomography-multivariate analysis*. J Comput Assist Tomogr, 2013. **37**(3): p. 450-7.
38. Sokhi, H.K., W.Y. Mok, and U. Patel, *Stage T3a renal cell carcinoma: staging accuracy of CT for sinus fat, perinephric fat or renal vein invasion*. Br J Radiol, 2015. **88**(1045): p. 20140504.
39. Karlo, C.A., et al., *Role of CT in the assessment of muscular venous branch invasion in patients with renal cell carcinoma*. AJR Am J Roentgenol, 2013. **201**(4): p. 847-52.
40. Karlo, C.A., et al., *CT of renal cell carcinoma: assessment of collecting system invasion*. AJR Am J Roentgenol, 2013. **201**(6): p. W821-7.
41. Hindman, N., et al., *Angiomyolipoma with minimal fat: can it be differentiated from clear cell renal cell carcinoma by using standard MR techniques?* Radiology, 2012. **265**(2): p. 468-77.
42. Kim, S., et al., *T1 hyperintense renal lesions: characterization with diffusion-weighted MR imaging versus contrast-enhanced MR imaging*. Radiology, 2009. **251**(3): p. 796-807.
43. Kim, J.H., et al., *Predicting the histology of small renal masses using preoperative dynamic contrast-enhanced magnetic resonance imaging*. Urology, 2012. **80**(4): p. 872-6.
44. Notohamiprodjo, M., et al., *Combined diffusion-weighted, blood oxygen level-dependent, and dynamic contrast-enhanced MRI for characterization and differentiation of renal cell carcinoma*. Acad Radiol, 2013. **20**(6): p. 685-93.

45. Pedrosa, I., et al., *MR classification of renal masses with pathologic correlation*. Eur Radiol, 2008. **18**(2): p. 365-75.
46. Sasiwimonphan, K., et al., *Small (<4 cm) renal mass: differentiation of angiomyolipoma without visible fat from renal cell carcinoma utilizing MR imaging*. Radiology, 2012. **263**(1): p. 160-8.
47. Sun, M.R., et al., *Renal cell carcinoma: dynamic contrast-enhanced MR imaging for differentiation of tumor subtypes--correlation with pathologic findings*. Radiology, 2009. **250**(3): p. 793-802.
48. Taouli, B., et al., *Renal lesions: characterization with diffusion-weighted imaging versus contrast-enhanced MR imaging*. Radiology, 2009. **251**(2): p. 398-407.
49. Karlo, C.A., et al., *Renal cell carcinoma: role of MR imaging in the assessment of muscular venous branch invasion*. Radiology, 2013. **267**(2): p. 454-9.
50. Li, X., et al., *Real-time contrast-enhanced ultrasound in diagnosis of solid renal lesions*. Discov Med, 2013. **16**(86): p. 15-25.
51. Chen, L., et al., *The diagnostic value of contrast-enhanced ultrasound in differentiating small renal carcinoma and angiomyolipoma*. Biosci Trends, 2015. **9**(4): p. 252-8.
52. Lu, Q., et al., *Differentiation of Renal Tumor Histotypes: Usefulness of Quantitative Analysis of Contrast-Enhanced Ultrasound*. AJR Am J Roentgenol, 2015. **205**(3): p. W335-42.
53. Xu, Z.F., et al., *Renal cell carcinoma and renal angiomyolipoma: differential diagnosis with real-time contrast-enhanced ultrasonography*. J Ultrasound Med, 2010. **29**(5): p. 709-17.
54. Xue, L.Y., et al., *Papillary renal cell carcinoma and clear cell renal cell carcinoma: Differentiation of distinct histological types with contrast - enhanced ultrasonography*. Eur J Radiol, 2015. **84**(10): p. 1849-56.
55. Ak, I. and C. Can, *F-18 FDG PET in detecting renal cell carcinoma*. Acta Radiol, 2005. **46**(8): p. 895-9.
56. Ho, C.L., et al., *Dual-tracer PET/CT in renal angiomyolipoma and subtypes of renal cell carcinoma*. Clin Nucl Med, 2012. **37**(11): p. 1075-82.
57. Zhang, J., et al., *Application of 18F-FDG PET/CT in diagnosis and management of renal tumors*. Chin J Med Imaging Technol, 2012. **28**(3): p. 548-551.
58. Deeks JJ, W.S., Davenport C, *Chapter 4: Guide to the contents of a Cochrane Diagnostic Test Accuracy Protocol*, in *Cochrane Handbook for Systematic Reviews of Diagnostic Test Accuracy Version 1.0.0.*, B.P. Deeks JJ, Gatsonis C, Editor. 2013, The Cochrane Collaboration.
59. Choudhary, S., et al., *Renal oncocytoma: CT features cannot reliably distinguish oncocytoma from other renal neoplasms*. Clin Radiol, 2009. **64**(5): p. 517-22.
60. Lee, Y., et al., *Does Computer-Aided Diagnosis Permit Differentiation of Angiomyolipoma Without Visible Fat From Renal Cell Carcinoma on MDCT?* AJR Am J Roentgenol, 2015. **205**(3): p. W305-12.
61. Seppala, N., et al., *Inter-rater agreement in the characterization of cystic renal lesions on contrast-enhanced MRI*. Abdom Imaging, 2014. **39**(6): p. 1267-73.
62. Rose, T.A., Jr. and J.W. Choi, *Intravenous Imaging Contrast Media Complications: The Basics That Every Clinician Needs to Know*. Am J Med, 2015. **128**(9): p. 943-9.

Danksagung

Großer Dank gilt Herrn Prof. Dr. med. Michael Staehler für die freundliche Aufnahme als Doktorandin und die intensive Betreuung bei der Fertigstellung der Dissertation sowie der damit verbundenen Publikation.

Herzlich möchte ich Frau Dr. med. Brigitte Ziegelmüller für die gute Zusammenarbeit und die Unterstützung und Motivation bei dieser Arbeit danken.

Herrn Dr. Thomas Lam (PhD) von der University of Aberdeen danke ich für den intensiven Austausch und die fachliche Beratung während der gesamten Phase meiner Arbeit sowie der Publikation. Frau Fiona Stewart von der University of Aberdeen gilt mein Dank für ihre wertvolle Unterstützung bei der Literaturrecherche. Frau Dr. Cathy Yuhong Yuan (PHD) möchte ich für die Hilfe bei der Übersetzung und Auswertung der chinesischen Studien danken.

Herrn PD Dr. Alexander Buchner danke ich für die statistische Beratung.

Schließlich möchte ich meinem Mann, Herrn Dr. Nikolai Blaumer, für seine liebevolle Unterstützung und Ermutigung gerade auch in schwierigen Phasen der Doktorarbeit von Herzen danken.

Eidesstattliche Versicherung

Vogel, Christina

Name, Vorname

Ich erkläre hiermit an Eides statt,
dass ich die vorliegende Dissertation mit dem Thema
Imaging In Renal Cell Carcinoma - A Systematic Review

selbständig verfasst, mich außer der angegebenen keiner weiteren Hilfsmittel bedient und alle Erkenntnisse, die aus dem Schrifttum ganz oder annähernd übernommen sind, als solche kenntlich gemacht und nach ihrer Herkunft unter Bezeichnung der Fundstelle einzeln nachgewiesen habe.

Ich erkläre des Weiteren, dass die hier vorgelegte Dissertation nicht in gleicher oder in ähnlicher Form bei einer anderen Stelle zur Erlangung eines akademischen Grades eingereicht wurde.

Ort, Datum

Unterschrift Doktorandin/Doktorand